



## A CASE OF CONCOMITANT NEOPLASIA IN A GRAMASREE (*Gallus domesticus*) BIRD

Received:

Accepted:

Post- mortem examination of a nine months old Gramasree layer revealed kidneys of both sides appearing as a large nodular mass of about 2 cm in diameter, hard in consistency with an irregular surface. The cut-surface revealed cystic spaces. Histopathological examination of the renal tissue revealed malformed glomeruli and irregular masses of distorted tubules. Groups of large irregular, cuboidal, undifferentiated cells with little tubular organization were also observed. The interstitium was flooded with immature lymphoid cells which exhibited pyroninophilic cytoplasm when stained with Methyl-green pyronin, thus suggesting a concomitant neoplasia of nephroblastoma and lymphoid leucosis.

Spontaneous nephro-blastomas or Wilm's tumour in poultry have been reported by various authors (Asdrubali *et al.*, 1995; Singh and Mohanty, 2007). These tumours originate from metanephric blastema and give rise to epithelial and mesenchymal structures with high degree of differentiation. They are unilateral, cystic and do not undergo metastasis (Saif, 2003; Singh and Mohanty, 2007).

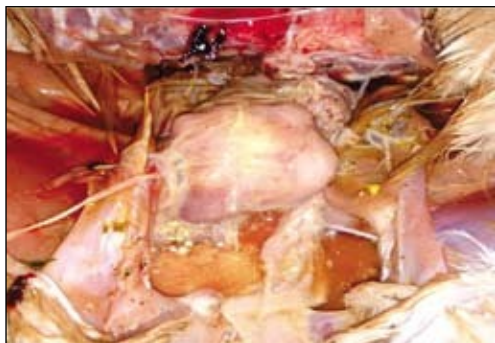Carcass of a nine months old Gramasree bird was brought for post-mortem examination to the Department of Veterinary Pathology, College of Veterinary and Animal Sciences, Mannuthy. Necropsy was conducted and the gross lesions were recorded. Tissue samples were collected in 10 per cent Neutral

Buffered Formalin for histopathological examination.

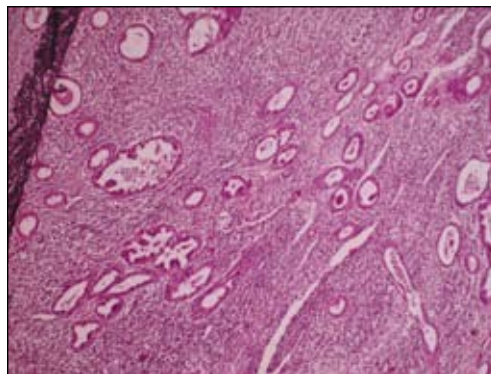
Post-mortem examination of the carcass revealed kidneys of both sides appearing as a large nodular mass of about 2 cm in diameter, hard in consistency with an irregular surface (Fig. 1). The cut-surface revealed cystic spaces. Histopathological examination of the renal tissue revealed epithelial structures varying from enlarged tubules with invaginations and malformed glomeruli. Irregular masses of distorted tubules showing little organisation and comprising of irregular, cuboidal and undifferentiated cells were observed. Protein rich fluid was found in some cysts lined with flattened epithelium. The interstitium was flooded with immature lymphoid cells (Fig.2). The lymphoid cells exhibited pyroninophilic cytoplasm when stained with Methyl-green pyronin (Bancroft and Stevens, 1996) which was suggestive of lymphoid leucosis.

The nodular appearance of the tumour and the presence of undifferentiated epithelial structures in nephroblastomas have been reported by earlier authors (David and Ashley, 1978; Saif, 2003; Singh and Mohanty, 2007). The histological appearance of lymphoid cells suggestive of lymphoid leucosis can be attributed to the concomitant appearance of neoplastic conditions which might be due to avian leucosis/ sarcoma virus which produce

1. Assistant Professor and corresponding author. email: [kkrithiga@rediffmail.com](mailto:kkrithiga@rediffmail.com)
2. MVSc Scholar
3. Associate Professor
4. Professor (Retd.)
5. Professor and Head



**Fig.1.** Kidneys appearing as a single, hard, nodular mass



**Fig. 2.** Enlarged tubules with invagination and malformed glomeruli, interstitium flooded with lymphoid cells. H&E x100.

a variety of tumours in birds (Payne and Purchase, 1992). The Avian Leucosis virus is capable of producing a variety of neoplasms including lymphoid leucosis, nephroblastoma, myelocytomas, hemangiosarcoma and non-neoplastic lesions. The present case could be such an infection which has resulted in concomitant neoplasia in the bird.

### Summary

In the present case, kidneys of both sides of a Gramasree bird appeared as large, hard, nodular mass with cystic spaces on post-mortem examination. On histopathology, epithelial structures varying from enlarged tubules with invaginations and malformed glomeruli along with immature lymphoid cell accumulation in interstitium was observed. The lymphoid cells exhibited pyroninophilic cytoplasm when stained with Methyl-green pyronin suggestive of lymphoid leucosis. Though there are many reports of nephroblastoma in poultry, a concomitant occurrence of nephroblastoma and lymphoid leucosis in a Gramasree bird is reported here.

### References

- Asdrubali, G., Franciosi, M.P., Mughetti, L., Coletti, M. and Cerrutisola, S. 1995. Naturally occurring nephroblastomas in light meat broilers. *Avian Pathol.* **24**: 45-53.
- Bancroft, J.D. and Stevens, A. 1996. *Theory and Practice of Histological Staining Techniques*. (4<sup>th</sup> Ed.). Churchill Livingstone, New York. p.148.
- David, J.B. and Ashley. 1978. *Evan's Histological Appearance of Tumours*. (3<sup>rd</sup> Ed.). Churchill Livingstone constable press Ltd., Edinburg. pp. 808-812.
- Payne, L.N. and Purchase, H.G. 1992. *Leukosis-sarcoma Group*. In: Calnek, B.W. (Ed.) *Diseases of Poultry*. (9<sup>th</sup> Ed.). Ames, Iowa State University Press. pp. 386-439.
- Saif, Y.M. 2003. *Diseases of Poultry*. (11<sup>th</sup> Ed.). Iowa State Press. pp. 489-491.
- Singh, S.D. and Mohanty, T.R. 2007. Nephroblastoma in a copper pheasant (*Syrnaticus soemmerringii*). *Indian J. Vet. Pathol.* **31**:76-77.

**K. Krithiga<sup>1\*</sup>, C. Purnima<sup>2</sup>, S. S. Devi<sup>1</sup>, Ajith Jacob George<sup>3</sup>, Mammen J. Abraham<sup>3</sup>, C. B. Manomohan<sup>4</sup>, and N. Vijayan<sup>5</sup>**  
Department of Veterinary Pathology  
College of Veterinary and Animal Sciences,  
Mannuthy, Thrissur- 680 651