



A retrospective study of acute kidney injury in dogs with renal resistive index as a prognostic indicator[#]

B.G. Rohini¹, Arun George^{2*}, N.P. Usha³, N. Madhavan Unny⁴, R. Ambily⁵, V.L. Gleeja⁶

Department of Veterinary Clinical Medicine, Ethics and Jurisprudence
College of Veterinary and Animal Sciences, Mannuthy, Thrissur- 680 651
Kerala Veterinary and Animal Sciences University, Kerala, India.

Citation: Rohini, B.G., George, A., Usha, N.P., Madhavan Unny, N., Ambily, R. and Gleeja, V.L. 2022. A retrospective study of acute kidney injury in dogs with renal resistive index as a prognostic indicator. *J. Vet. Anim. Sci.* **53**(4):

DOI: <https://doi.org/10.51966/jvas.2022.53.4>.

Received: 27.04.2022

Accepted: 13.05.2022

Published: 31.12.2022

Abstract

Doppler ultrasonography is relatively a new method for evaluation of the renal diseases in dogs. This study was conducted to evaluate the efficacy of renal resistive index (RRI) in diagnosis and prognosis of acute kidney injury (AKI) in dogs and to ascertain its correlation with other renal parameters. Twenty-seven dogs with AKI along with ten clinically healthy dogs were evaluated. The aetiology of AKI was multifactorial which included viper snake envenomation, pyometra, Babesia gibsoni infection, canine parvo viral infection, Ehrlichia canis infection, leptospiral infection, bone meal poisoning and tetracycline-induced nephrotoxicity. Dogs with AKI were characterized into five grades as per the guidelines provided by International Renal Interest Society. Parameters such as blood urea nitrogen (BUN), creatinine, urine output, urine protein-creatinine (UPC) ratio and blood pressure were estimated. Both BUN and creatinine were significantly higher in affected dogs. Majority of the dogs with AKI were oliguric and had the presence of proteinuria, occult blood and leucocytes on urine dipstick examination. Urine Protein-Creatinine ratio was increased whereas no significant variation was noticed in blood pressure of dogs with AKI. B-mode ultrasonography of kidneys revealed renomegaly, hyperechoic cortex, decreased cortico-medullary differentiation and loss of architecture in majority of the dogs with AKI. Renal resistive index was significantly increased in AKI and a positive correlation was established between RRI and serum creatinine but

[#]Part of MVSc thesis submitted to Kerala Veterinary and Animal Sciences University, Pookode, Wayanad, Kerala

1. M.V.Sc scholar
2. Assistant Professor
3. Professor and Head
4. Associate Professor
5. Assistant Professor, Department of Veterinary Microbiology
6. Assistant Professor, Department of Statistics

*Corresponding author: arun@kvasu.ac.in Ph. 9447747992

Copyright: © 2022 Rohini et al. This is an open access article distributed under the terms of the Creative Commons Attribution 4.0 International License (<http://creativecommons.org/licenses/by/4.0/>), which permits unrestricted use, distribution, and reproduction in any medium, provided the original author and source are credited.

not with UPC ratio, blood pressure and size of kidneys. Re-evaluation of RRI seven days post treatment showed considerable reduction. It was concluded that an increase in RRI was associated with severity of renal parenchymal injury in AKI and reduction of RRI post-treatment indicated favorable prognosis.

Key words: Dog, renal resistive index, acute kidney injury

Kidneys are uniquely susceptible to acute injury as they receive approximately 20% of cardiac output, the highest of any organ in the body in relation to organ weight (Epstein, 1995). In acute kidney injury (AKI), the B-mode ultrasonogram often do not represent the severity of renal damage. The findings are usually normal despite severe renal dysfunction (Tublin *et al.*, 2003).

Doppler-based ultrasonography is a simple and non-invasive investigative technique used for the early diagnosis of AKI by assessing renal resistive index (RRI) (Ninet *et al.*, 2015). The resistive index (RI) measures the arterial resistance in peripheral vessels by calculating the ratio between the peak systolic velocity (PSV) and the end diastolic velocity (EDV) using the equation, $(RI = (PSV - EDV) / PSV)$ (Tipisca *et al.*, 2016). The normal RRI value of an adult dog varied from 0.56 to 0.67 (Morrow *et al.*, 1996). Renal resistive index above the upper limit indicated the presence of renal diseases (Bragato *et al.*, 2017).

Materials and methods

Selection of animals

A total of 70 dogs presented to University Veterinary hospitals at Kokkalai and Mannuthy with clinical signs suggestive of renal involvement such as anorexia or inappetence, vomiting, oliguria, polyuria and or melena were screened to identify 27 dogs with acute renal involvement and were selected for this study under Group II. Ten apparently healthy dogs brought for general check-up or prophylactic vaccination were taken as the control group to obtain normal values of parameters under study as Group I.

Clinico-pathological examination of patient

All cases were subjected to thorough physical examination, imaging studies and paraclinical tests to evaluate the renal function. An AKI was established based on history, clinical signs, laboratory tests and ultrasonographic findings. As per International Renal Interest Society (IRIS, 2016) AKI was divided into five grades based on blood creatinine and urine formation. Blood urea nitrogen and serum creatinine were estimated on the first day using a semi-automatic analyser (Mispa Viva 2578-10/17, Agappe diagnostics Ltd). Urine was collected by catheterisation on the day of admission into sterile vials and subjected to analysis using DIRUI H series urinalysis strips (Uristick- Dirui Industrial Co. Ltd), microscopic examination and microbial culture. Urine output was measured and recorded in terms of ml/kg/hr. Urine protein-creatinine ratio was measured using fully automated machine, COBAS 6000, ROCHE. Blood pressure was estimated by an oscillometric method using automatic Omron Hem 7121J blood pressure monitor.

Ultrasonographic examination

Ultrasonographic examination was carried out as per standard protocols (d'Anjou and Penninck, 2015) using Mindray DC 6 Vet Ultrasound Machine. Both kidneys were assessed for their size, and relative parenchymal echogenicity. Kidney size was obtained by calculating a ratio of length of kidney and diameter of aorta (Fig. 1). Doppler ultrasonography was performed using high frequency probe with colour flow. A sample volume size of 1-2mm was placed in interlobar arteries and a subsequent pulse Doppler interrogation was obtained (Fig. 2). A total of 3-5 waveforms were used to determine mean RRI in 2 or 3 different locations of renal parenchyma. The ultrasound machine automatically calculates the RRI after manual delimitation of peak systolic and end diastolic velocity (Fig. 2).

Statistical analysis

Statistical analysis was performed using One-way Anova and correlation between

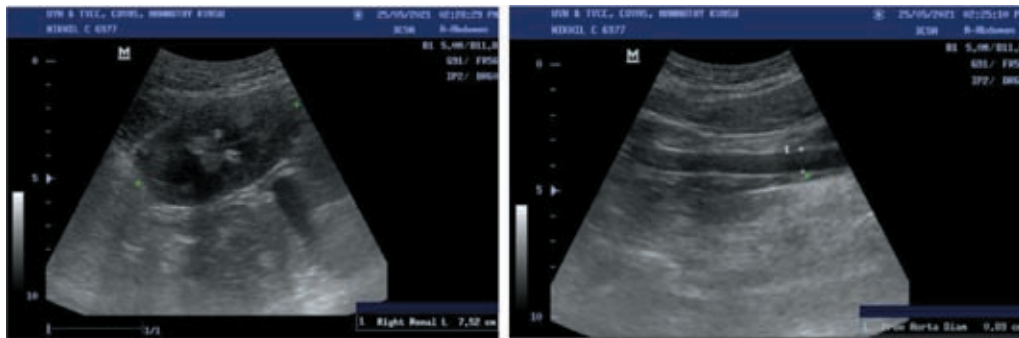


Fig. 1. Ultrasound image showing measurement of kidney size by measuring kidney length (between cursors) and aorta diameter (right) to obtain a ratio.

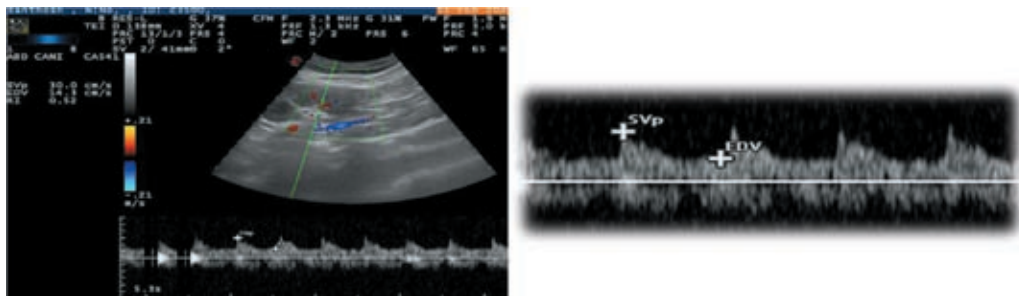


Fig. 2. Pulsed wave Doppler ultrasound image showing sample location (interlobar artery) in a healthy dog (Left) and right image showing delimitation of peak systolic velocity (PSV) and end diastolic velocity (EDV) from pulsed waves.

RRI and other parameters were obtained using Pearson's correlation. Statistical significance was settled ($p < 0.05$) and results were expressed as mean \pm standard error.

Results and discussion

Group I (control) included 6 males and 4 females with mean age of 4.6 years ranging from 3 months to 7 years. Group II (AKI group) included 15 males and 12 females with mean age of 4.6 years ranging from 7 months to 12 years.

Causes and grading of AKI

The causes of AKI identified in this study included viper snake envenomation (3 cases), pyometra (3 cases), *Babesiagibsoni* infection (3 cases), canine parvo viral infection (1 case), *Ehrlichia canis* infection (1 case), Leptospiral infection (1 case), fertilizer poisoning (1 case) and tetracycline-induced nephrotoxicity (1 case). Reason remained undetermined in thirteen cases. Acute kidney injury due to viper

bite envenomation, pyometra, leptospirosis and canine parvo viral infection might result from toxemia, sepsis, dehydration, hypovolemia, and hypotension (Grauer, 2005; Van den Berg *et al.*, 2018). In babesiosis, injury to kidney possibly developed due to reduced glomerular filtration rate (GFR) and formation of urine methaemoglobin which is toxic to kidneys as suggested by Lobetti *et al.* (1996). The deposition of immune complexes in the kidneys triggered membranoproliferative glomerulonephritis in dogs affected with ehrlichiosis (Pinho *et al.*, 2016). Some of the undetermined cases could be infectious as bacterial growth was noticed on microbial culture of urine collected aseptically by catheterization. However, a confirmation of the presence of bacteria in pelvis or renal parenchyma was not done and is beyond the scope of this research.

As per IRIS guidelines, out of 27 dogs with AKI, two dogs were in AKI grade 1, six in grade 2, five in grade 3, seven in grade 4 and seven in grade 5 as depicted in Table 1.

Table 1. Grading of acute kidney injury

AKI grades (serum creatinine)	Aetiology	Number of cases
Grade 1 (<1.6 mg/dL)	Viper bite (1) idiopathic (1)	02
Grade 2 (1.7-2.5 mg/dL)	<i>Babesiagibsoni</i> (1), fertilizer poisoning (1) idiopathic (4)	06
Grade 3 (2.6-5.0 mg/dL)	Viper bite (2), Leptospirosis (1), Canine parvo viral (1) idiopathic (1)	05
Grade 4 (5.1-10.0 mg/dL)	<i>Babesiagibsoni</i> (1), pyometra (3) idiopathic (3)	07
Grade 5 (>10.0 mg/dL)	<i>Babesiagibsoni</i> (1) <i>Ehrlichia canis</i> (1), tetracycline-induced nephrotoxicity (1) idiopathic (4)	07
Total		27

Clinico-pathological findings

In Group I, the dogs had clear, light yellow coloured urine with an acidic pH and a specific gravity of 1.025. The urine sediments were inactive on light microscopic examination. In Group II, light yellow urine was noticed in 15 cases, dark yellow urine in 7 cases and greenish yellow urine in 5 cases. The pH was acidic and the mean specific gravity was 1.023 (1.010 - 1.030). Dipstick urinalysis showed mild to moderate level of proteinuria in 23 cases, occult blood in 19 cases, and leucocytes in 15 cases. Similar findings were recorded by Kandula and Karlapudi (2015). Turbidity of urine was noticed in 17 cases. On sediment examination, there were presence of RBCs and pus cells in 9 cases, bacteria in 7 cases and trace amount of hyaline cast in a single case. Changes in urine volume, increase in turbidity and changes in urine sediments are indicators of acute ongoing tubular damage (Guess and Grauer, 2017).

Dogs with AKI had variation in urine output. Oliguria was noticed in 13 cases which resulted from decreased renal blood flow accompanied by decreased GFR (Guyton and Hall, 2006). Polyuria (n=5) indicated recovery stages of AKI due to compensatory mechanism and anuria (n=5) indicated either early or end stages of renal failure (Subapriya *et al.*, 2020). Normal urine output was noticed in four cases.

The mean values of BUN in Group I and Group II were 19.00 ± 1.53 and 85.92 ± 7.79 mg/dL, respectively and serum creatinine were 1.01 ± 0.09 and 6.72 ± 1.12 mg/dL,

respectively. Both BUN and serum creatinine were significantly higher in dogs with AKI than in healthy group (Table 2) which indicated renal injury on exclusion of pre-renal causes of azotemia (Guess and Grauer, 2017).

On microbial culture of urine, 10 out of 27 dogs yielded Gram negative bacilli organisms. This was similar to findings of Kandula and Karlapudi (2015) who isolated *E. coli*, *Staphylococcus* and *Pseudomonas* organisms from dogs with renal insufficiency.

In Group II, 19 out of 27 dogs were proteinuric (UPC ratio > 0.5) with mean UPC ratio of 2.54 ± 0.98 whereas Group I animals had UPC ratio of 0.54 ± 0.10 . The huge intra-group variation in UPC ratio in AKI could be due to variation in the severity of renal damage. These results coincided with Van den Berg *et al.* (2018), Sant 'Anna *et al.* (2019) and de Oliveira Paes-Leme *et al.* (2021). Increase in UPC ratio level in AKI indicated impaired glomerular filtration mechanism, tubular cellular damage and impaired tubular resorption resulting in leakage of proteins into urine (Cole *et al.*, 2020).

The systolic, diastolic and mean arterial pressure (MAP) of Group I was 130.4 ± 4.0 , 86.20 ± 2.4 and 100.70 ± 2.73 mm of Hg, respectively and that of Group II was 139.6 ± 4.6 , 93.03 ± 4.4 and 108.37 ± 4.26 mm of Hg, respectively. The MAP did not show significant difference in between groups at $p < 0.05$ (Table 2).

Ultrasonographic examination results

Sonograms revealed increased renal cortical echogenicity ($n=27$), decrease in cortico-medullary differentiation ($n=15$) and loss in renal architecture ($n=7$) in Group II whereas no abnormalities were noticed in Group I (Fig. 3). In general, these changes indicated a diffuse inflammatory or infiltrative or degenerative disease process (Kanaran, 2009). Interstitial and glomerular nephritis, acute tubular nephrosis or necrosis and end-stage renal disease can cause renal hyperechogenicity (Eubiget *et al.*, 2005). Hyper echogenicity of renal cortex and loss of cortico-medullary differentiation was reported in pyometra and leptospiral infection (Kanaran, 2009). Elgazzaret *et al.* (2021) reported hyper echogenicity of renal cortex in dogs with gentamicin-induced AKI.

Mean kidney length-aorta diameter ratio in Group I and II was 7.89 ± 0.25 and 9.59

± 0.62 , respectively indicating renomegaly in dogs with AKI. This statement was in agreement with d'Anjoo and Penninck (2015) who reported enlargement in size of kidneys affected with acute processes and Gasseret *et al.* (2020) who recorded renomegaly in dogs with AKI due to pyometra.

Resistive index is used as indicator of vascular resistance in both veterinary and human medicine. Normal value of RRI in healthy dogs range from 0.56 to 0.67 (Morrow *et al.*, 1996, Ostrowska *et al.*, 2016). In this study, statistical analysis did not reveal any significant difference between right RRI and left RRI in both the groups. Hence the mean value was obtained and used for further correlations. The mean RRI was 0.59 ± 0.01 in Group I and 0.70 ± 0.02 in Group II (Table 2) (Fig. 4&5). There was significant increase in RRI in AKI. Decreased flow of blood in renal arteries secondary to renal injury caused an increase in RRI (Chang *et al.*,

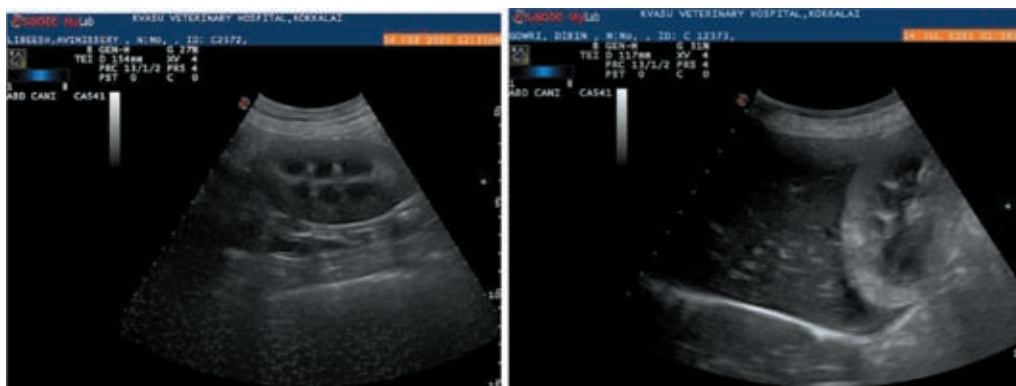


Fig. 3. Left image showing kidney of a healthy dog that is normal in size (K/Ao ratio 5.06), Renal cortex (C) is more echogenic than medulla (M) is separated by several lobulated segments by the presence of linear echogenicity representing borders of the interlobar vessels. Right image showing the right kidney of a dog with AKI. Renal cortex (C) is hyperechoic than liver, increased in size (K/Ao; 12.09), reduced cortico-medullary differentiation and loss in architecture.

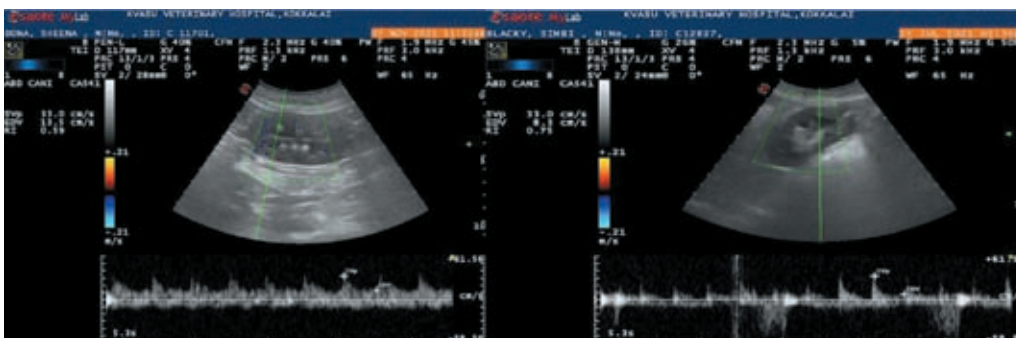


Fig. 4. Doppler ultrasonographic measurement of RRI in interlobar artery of healthy kidney was 0.59 (left) and 0.75 in AKI (right).

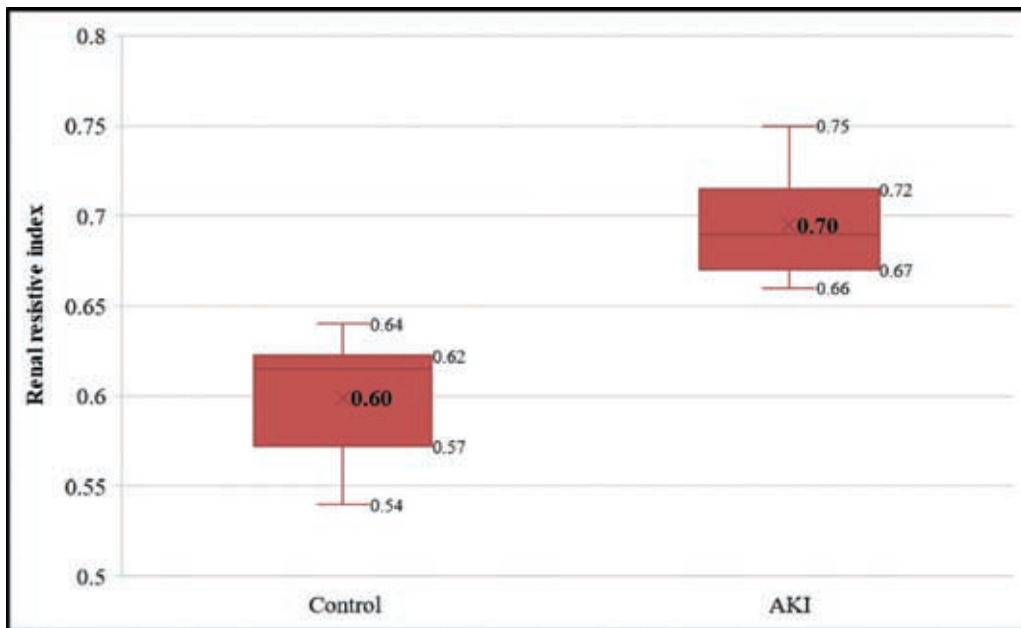


Fig. 5. Whisker-plot of the RRI distribution in healthy dogs and dogs with AKI

Table 2. Renal parameters of healthy dogs and dogs with AKI (Mean \pm SE)

Parameters	Group I (Healthy dogs) n=10	Group II (Dogs with AKI) n=27	p-value
Blood Urea Nitrogen (mg/dL)	19.00 \pm 1.53	85.92 \pm 7.79**	<0.001
Serum Creatinine (mg/dL)	1.01 \pm 0.09	6.72 \pm 1.12*	0.03
UPC ratio	0.54 \pm 0.10	2.54 \pm 0.98	0.16
Mean arterial pressure (mm of Hg)	100.70 \pm 2.73	108.37 \pm 4.26	0.29
K/Ao ratio	7.29 \pm 0.25	9.59 \pm 0.62	0.01
Left RRI	0.61 \pm 0.01	0.70 \pm 0.02**	<0.001
Right RRI	0.60 \pm 0.00	0.70 \pm 0.01*	0.01
Mean RRI (0 th day)	0.59 \pm 0.01	0.70 \pm 0.02*	0.01
7 th day post treatment			
Serum creatinine (mg/dL)	-	5.95 \pm 1.14	-
Mean RRI	-	0.67 \pm 0.00	-

*-significant at $p < 0.05$, **-significant at $p < 0.01$

2010). These results concurred with Novellas *et al.* (2007); Constantinescu *et al.* (2015) and Elgazzaret *et al.* (2021).

Treatment outcome

All dogs in Group II were treated with specific, symptomatic and supportive therapy for one week. After one week serum creatinine value decreased in all the dogs except five. Of these five dogs, two dogs with pyometra and one with leptospirosis died during the second

week of treatment due to sepsis and secondary complications. In all other cases a re-evaluation of RRI showed a considerable decrease which indicated a favourable prognosis. (Table 2 and Fig. 6). This coincides with Daley *et al.* (1994) and Rivers *et al.* (1997) who reported decrease in RRI after treatment for AKI in dogs.

Statistical analysis with Pearson correlation revealed positive correlation ($p < 0.01$) between RRI and serum creatinine but not with UPC ratio, blood pressure and kidney

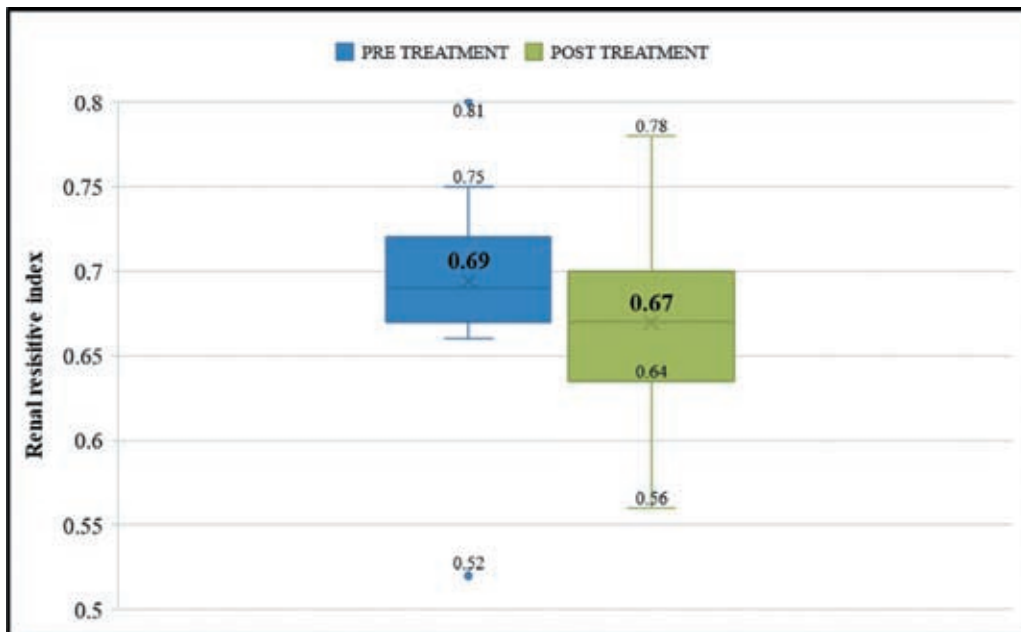


Fig. 6. Whisker-plot representing post-treatment values of RRI

Table 3. Correlation between RRI and other parameters in dogs with AKI

Parameters		Serum creatinine (mg/dL)	UPC ratio	Blood pressure (mm of Hg)	Kidney size
RRI	Pearson correlation	0.516**	-0.164	0.179	-0.031
	p-value	<0.001	0.41	0.37	0.87

**-significant at $p < 0.01$

size (Table 3). In both humans and dogs, RRI has been reported to correlate positively with serum creatinine (Kodaet *al.*, 2000; Novellas *et al.*, 2008). The evaluation of RRI and its interpretation with serum creatinine is important in the diagnosis of renal injury pre-treatment and assessment of response post-treatment as high RRI with renal azotemia strongly suggested a persistent renal insult. A correlation of RRI with UPC ratio, blood pressure and kidney size were not mentioned by IRIS.

Conclusion

On the basis of this study, it is concluded that aetiologies of AKI were multifactorial and characterisation into various stages would help in better assessment and management of the condition. Major sonographic findings of AKI include renomegaly, hyper echogenicity of cortex, decrease in cortico-medullary differentiation and loss in renal architecture.

Renal resistive index increases with AKI. A correlation between RRI and creatinine could be found in dogs with AKI. Reduction in RRI after treatment correlates with favourable prognosis.

Conflict of interest

The authors declare that they have no conflict of interest.

References

- Bragato, N., Borges, N.C. and Fioravanti, M.C. 2017. B-mode and Doppler ultrasound of chronic kidney disease in dogs and cats. *Vet. Res. Commun.* **41**: 307-315.
- Chang, Y.J., Chan, I.P., Cheng, F.P., Wang, W.S., Liu, P.C. and Lin, S.L. 2010. Relationship between age, plasma renin activity, and renal resistive index in dogs. *Vet. Radiol. Ultrasound*. **51**: 335-337.

- Cole, L.P., Jepson, R., Dawson, C. and Humm, K. 2020. Hypertension, retinopathy, and acute kidney injury in dogs: A prospective study. *J. Vet. Intern. Med.* **34**: 1940-1947.
- Constantinescu, R., Crivineanu, V., Goran, G., RalucaTeodora, N.A.E. and Codreanu, M.D. 2015. Evaluation of renal vascular resistance and blood pressure in dogs with different renal diseases. *Scient. Works Ser. C. Vet. Med.* **61**:178-183.
- Daley, C.A., Finn-Bodner, S.T. and Lenz, S.D. 1994. Contrast-induced renal failure documented by color-Doppler imaging in a dog. *J. Am. Anim. Hosp. Assoc.* **30**: 33-37.
- d'Anjou, M.A. and Penninck, D. 2015. Kidney and Ureters. In: Penninck, D and d'Anjou, M.A. (ed.), *Atlas of Small Animal Ultrasonography*. (2nd Ed.). Ames. Wiley Blackwell, pp. 331-61.
- de Oliveira Paes-Leme, F., Souza, E.M., Paes, P.R.O., Gomes, M.G., Muniz, F.S., Campos, M.T.G., Peixoto, R.B., de Melo, P.D.V., Arndt, M.H. and Val, A.C. 2021. Cystatin C and Iris: Advances in the Evaluation of Kidney Function in Critically Ill Dog. *Front. Vet. Sci.* **8**: 1-5.
- Elgazzar, Y.M., Ghanem, M.M., Abdel-Raof, Y.M., Kandiel, M.M. and Helal, M.A. 2021. Evaluation of symmetric dimethylarginine and Doppler ultrasonography in the diagnosis of gentamicin-induced acute kidney injury in dogs. *Environ. Sci. Pollut. Res.* **29**: 1-11.
- Epstein, F.H. 1995. Hypoxia of the renal medulla - Its implications for disease. *N. Engl. J. Med.* **332**: 647-655.
- Eubig, P.A., Brady, M.S., Gwaltney-Brant, S.M., Khan, S.A., Mazzaferro, E.M. and Morrow, C.M. 2005. Acute renal failure in dogs after the ingestion of grapes or raisins: A retrospective evaluation of 43 dogs (1992-2002). *J. Vet. Intern. Med.* **19**:663-674.
- Gasser, B., Uscategui, R.A.R., Maronezi, M.C., Pavan, L., Simões, A.P.R., Martinato, F., Silva, P., Crivellenti, L.Z. and Feliciano, M.A.R. 2020. Clinical and ultrasound variables for early diagnosis of septic acute kidney injury in bitches with pyometra. *Sci. Rep.* **10**: 1-12.
- Grauer, G.F. 2005. Early detection of renal damage and disease in dogs and cats. *Vet. Clin. North Am. Small Animal Pract.* **35**:581-596.
- Guess, S.C. and Grauer, G.F. 2017. Acute kidney injury. In: Elliot, J. and Grauer, G.F. (ed.), *BSAVA Manual of Canine and Feline Nephrology and Urology* (3rd Ed.). BSAVA England, pp. 246-253.
- Guyton, A.C. and Hall, J. 2006. *Textbook of Medical Physiology*. (12th Ed.) Elsevier, Philidelphia, PA, USA, 1112p.
- IRIS [International Renal Interest Society grading of acute kidney injury (AKI)]. 2016. Available: <http://www.iris-kidney.com/guidelines/grading.html> [2 Jan. 2022].
- Kandula, S. and Karlapudi, S.K. 2015. Urinalysis: a critical laboratory test for diagnosis of renal insufficiency in dogs. *Anim. Sci. Report.* **9**: 75-80.
- Kanaran, P. 2009. Clinico-biochemical and ultrasonographic evaluation of renal failure in dogs. *M.V.Sc. thesis*, Kerala Veterinary and Animal Sciences University, Pookode, 123p.
- Koda, M., Murawaki, Y. and Kawasaki, H. 2000. Renovascular resistance assessed by color Doppler ultrasonography in patients with chronic liver diseases. *J. Gastroenterol. Hepatol.* **15**: 1424-1429.
- Lobetti, R.G., Reyers, F. and Nesbit, J. 1996. The comparative role of haemoglobinaemia and hypoxia in the development of canine babesial nephropathy. *J. S. Afr. Vet. Assoc.* **67**:188-198.
- Morrow, K.L., Salman, M.D., Lappin, M.R., Wrigley, R. 1996. Comparison of the

- resistive index to clinical parameters in dogs with renal disease. *Vet. Radiol. Ultrasound*. **37**: 193–199.
- Ninet, S., Schnell, D., Dewitte, A., Zeni, F., Meziani, F. and Darmon, M. 2015. Doppler-based renal resistive index for prediction of renal dysfunction reversibility: a systematic review and meta-analysis. *J. Crit. Care*. **30**: 629-635.
- Novellas, R., de Gopegui, R.R. and Espada, Y. 2008. Increased renal vascular resistance in dogs with hepatic disease. *Vet. J.* **178**: 257-262.
- Novellas, R., Espada, Y. and Ruiz de Gopegui, R. 2007. Dopplerultrasonographic estimation of renal and ocular resistive and pulpability indices in normal dogs and cats. *Vet. Radiol. Ultrasound*. **48**: 69–73.
- Ostrowska, J., Kielbowicz, Z., Zaleska-Dorobisz, U., Atamaniuk, W., Pietsch-Fulbiszewska, A. and Kinda, W. 2016. Resistive index (RI) obtained in renal interlobar arteries of normal dogs and cats by means of Dopplerultrasonography. *Pak. Vet. J.* **36**: 45-48.
- Pinho, F.A., Prianti, M.G., Braga, J.F., Pires, L.V., França, S.A. and Silva, S.M. 2016. Renal histopathological changes in dogs naturally infected with *Ehrlichia canis*. *Braz. J. Vet. Pathol.* **9**: 2-15.
- Rivers, B.J., Walter, P.A., Polzin, D.J. and King, V.L. 1997. Duplex Doppler estimation of intrarenal peripelvic resistive index in dogs and cats with renal disease. *J. Vet. Intern. Med.* **11**: 250-260.
- Sant'Anna, M.C., Martins, G.F., Flaiban, K.K., Trautwein, L.G. and Martins, M.I. 2019. Protein-to-creatinine urinary in the early diagnosis of renal injury in canine pyometra. *Pesqui. Vet. Bras.* **39**: 186-191.
- Subapriya, S., Vairamuthu, S., Chandrasekar, M., Balagangatharathilagar, M., Ramesh, S., Areshkumar, M. and Thangaraj, M.J. 2020. Clinicopathological profile of canine renal disorders. *J. Entomol. Zool. Stud.* **8**: 770-774.
- Tipisca, V., Murino, C., Cortese, L., Mennonna, G., Auletta, L., Vulpe, V. and Meomartino, L. 2016. Resistive index for kidney evaluation in normal and diseased cats. *J. Feline Med. Surg.* **18**: 471-475.
- Tublin, M.E., Bude, R.O. and Platt, J.F. 2003. The resistive index in renal Doppler sonography: where do we stand. *Am. J. Roentgenol.* **180**: 885-892.
- Van den Berg, M.F., Schoeman, J.P., Defauw, P., Whitehead, Z., Breemers, A., Goethals, K., Daminet, S. and Meyer, E. 2018. Assessment of acute kidney injury in canine parvovirus infection: Comparison of kidney injury biomarkers with routine renal functional parameters. *Vet. J.* **242**: 8-14. ■