



A veterolegal case of cassava plant toxicity in malabari goats

C. Prasad ¹, Ajith Jacob George², C. Divya³, S.S. Devi⁴, Mammen J. Abraham⁵

Department of Veterinary Pathology, College of Veterinary and Animal Sciences,
Mannuthy, Thrissur – 680651

Citation: Prasad, C., George, A. J., Divya, C., Devi, S.S. and Abraham, M. J. 2020. A veterolegal case of Cassava plant toxicity in Malabari goats. *J. Vet. Anim. Sci.* 51(1): 91-93

Received : 21.03.2019

Accepted : 18.05.2019

Published : 01-01-2020

Cassava (*Manihot esculenta*) plant is a perennial woody shrub belonging to the family Euphorbiaceae originated from South America. It is an annual crop mostly cultivated in the tropical and sub-tropical regions. Cassava plant is considered as one of the most important energy source for humans and animals due to its efficiency in converting solar energy into carbohydrates. Thang *et al.* (2010) reported that foliage by products of the plant can be used as feed supplements and is a good source of protein for small ruminants. Fresh cassava foliage or cassava hay is also in practice of being fed to ruminants with good results in animals adapted to the consumption of the plant. Cassava foliage is rich in cyanogenic glycosides among which leaves has the higher concentration compared to roots (Bokanga, 1994). The cyanogenic glycosides in cassava are linamarin and lotaustralin, which gets released from leaves following mastication and get transformed to hydrogen cyanide (HCN) by enzymatic action of β -glycosidase or α -hydroxynitrile lyase secreted by gut bacteria. Cyanide is generally considered toxic to animals due to its inherent capacity to bind with iron, manganese and copper ions, which act as functional groups of many active enzymes of cytochrome respiratory chain for ATP production. Cessation of these ions results in energy deprivation (Zagrobelny *et al.*, 2004). The symptoms of acute cassava foliage toxicity include ptyalism, vomiting, excitement, staggering, paralysis, convulsions, coma and death. Symptoms may not be evident in case of chronic exposure to low doses of cyanogenic glycosides. Sheep and goat are highly susceptible to HCN toxicity than monogastric animals due to its rapid hydrolysis by rumen microbes (Kuma, 1992). A case of cassava leaf toxicity confirmed in five goat carcasses is detailed herein.

Carcasses of five white Malabari goats from Athirapally, Kerala were presented to the Department of Veterinary Pathology, College of Veterinary and Animal Sciences, Mannuthy for veterolegal post-mortem examination with the suspicion of malicious poisoning. Systematic autopsy was conducted and gross lesions were recorded. The representative tissue samples were collected in 10 per cent neutral buffered formalin for histopathological examination (Luna, L.G.,

1. M.V.Sc Scholar
2. Professor and Head, Dept of Veterinary Pathology, CVAS, Pookode, Wayanad
- 3, 4. Assistant Professor
5. Associate Professor & Head

Copyright: © 2020 Prasad et al. This is an open access article distributed under the terms of the Creative Commons Attribution 4.0 International License (<http://creativecommons.org/licenses/by/4.0/>), which permits unrestricted use, distribution, and reproduction in any medium, provided the original author and source are credited.

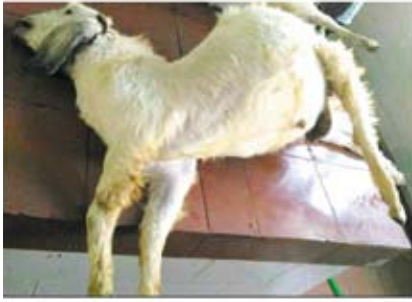

Fig 1: Bloated abdomen

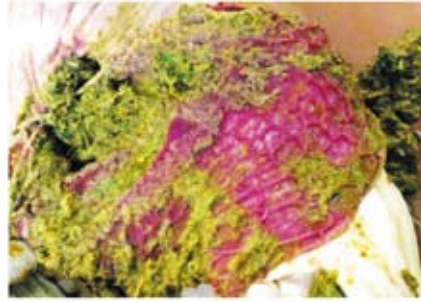

Fig 2: Reticulitis with grounded cassava leaf content

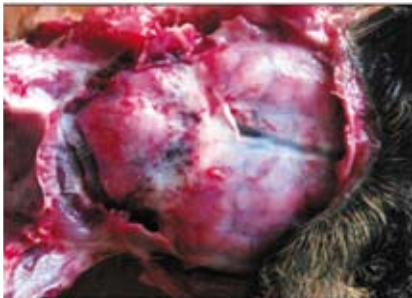

Fig 3: Multifocal petechial hemorrhages in meninges and cerebellum

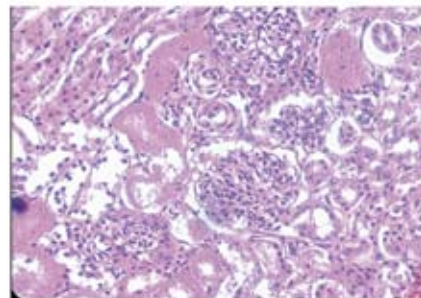


Fig 4: Kidney - Tubular necrosis- H& E x 400

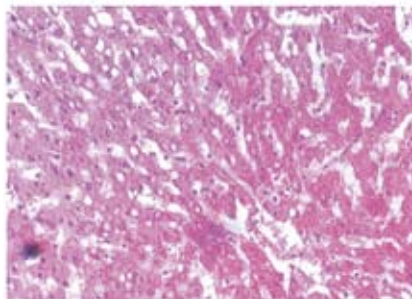


Fig 5: Liver - Vacuolation in hepatocytes and disruption in the hepatic cords - H& E x 400

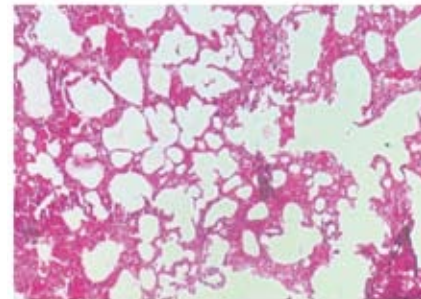


Fig 6: Lung - Pulmonary congestion and edema - H& E x 100

1968). Tissue samples along with stomach contents were preserved in brine solution and sent to the laboratory of Chemical Examiner to Government for toxicological examination.

All the five carcasses were in good condition and presented with bloated abdomen and stiff limbs (Fig. 1). On opening the carcasses a strong smell of bitter almond suggesting the possibility of cyanide poisoning could be observed. Gross examination revealed rumenitis, reticulitis, omasitis and hemorrhagic abomasitis with the mucosal layer peeling off easily in all the four compartments of stomach (Fig. 2). The fore stomach was found distended with semi digested remnants of trifoliolate leaves resembling cassava. Examination of

intestines revealed catarrhal enteritis. Severe multifocal hemorrhages could be observed in the cerebellum and meninges (Fig. 3). Remarkable pale coloration of liver and kidneys were noticed. Examination of thoracic cavity unveiled pulmonary congestion and edema. On microscopic examination, intestinal lumen was presented with necrotic remnants of denuded villi. Renal tubular lumen revealed the presence of epithelial casts due to deposition of desquamated tubular epithelial cells within (Fig. 4). Microscopic examination of liver revealed sinusoidal congestion, disruption in arrangement of hepatocytes and vacuolation inside hepatocytes (Fig. 5). Pulmonary congestion, oedema and emphysema (Fig. 6) were the other remarkable histopathologic

lesions noticed. Certificate of chemical analysis from the regional chemical examiner's laboratory confirmed the presence of hydrocyanic (HCN) acid in all the samples including lungs, heart, liver, kidneys, brain, body fat, stomach and intestine upon performing alkaline picrate test. Spectrophotometric analysis also revealed the presence of HCN in stomach contents. Sotoblanco and Gorniak (2010) studied the effect of cassava leaves intake in goats and observed vacuolation in the hepatocytes which is similar to the results of the present study. Sousa *et al.* (2002) also reported similar findings of degenerative and cytoplasmic vacuolar changes in the hepatocytes of rats with cyanide toxicity. The cause of death of goats in the present case was attributed to cyanide poisoning consequent to consumption of cassava leaves. The gross and histologic alterations observed here were found comparable to those described by other researchers in the field.

Summary

Carcasses of five white Malabari breed of goats from Athirapally, Kerala suspecting intentional poisoning were presented to the Department of Veterinary Pathology, College of Veterinary and Animal Sciences, Mannuthy for veterolegal post-mortem examination. External examination revealed bloated abdomen in all the carcasses. Characteristic bitter almond odour could be noticed upon opening the distended rumen. Cassava leaves could be observed inside the rumen, reticulum, omasum and abomasum. Hemorrhagic reticulitis with presence of leaf remnants, pulmonary congestion, multifocal petechial hemorrhages in brain, pale discolouration of both kidneys and catarrhal enteritis were the other lesions noticed. Rumen contents were sent to the Chemical Examiner to Government for toxicological examination and the result confirmed cyanide toxicity. Histopathological examination revealed necrosis of villi in intestine, tubular degeneration in kidneys, pulmonary emphysema and congestion, sinusoidal congestion and vacuolation of hepatocytes in liver. Based on the gross examination, histopathological observations and chemical examination results, the case was diagnosed

as cyanide poisoning possibly due to excessive consumption of Cassava leaves.

Acknowledgements

The authors would like to acknowledge the staff members and colleagues of Department of Veterinary Pathology, College of Veterinary and Animal Sciences, Mannuthy for their valuable support.

References

- Bokanga, M. 1994. Distribution of cyanogenic potential in cassava germplasm. *Agronomic Res.* **64(4)**: 117-124.
- Kuma, R. 1992. Anti-nutritional factors, the potential risks of toxicity and methods to alleviate them. Speedy, A., Pugliese, P. (Eds.). In: Legume Trees and Other Fodder Trees as Protein Sources for Livestock, FAO, Rome, 145-160p.
- Luna, L.G. 1968. Manual of Histologic Staining Methods of the Armed Forces Institute of Pathology. 3rd ed., McGraw Hill Book Company, New York. 207.
- Soto-Blanco, B. and Gorniak, S.L. 2010. Toxic effects of prolonged administration of leaves of cassava (*Manihot esculenta crantz*) to goats. *Experimental and Toxicol. Pathol.* **62**: 361-366.
- Sousa, A.B., Soto-Blanco, B., Guerra, J.L., Kimura, E.T., Gorniak, S.L. 2002. Does prolonged oral exposure to cyanide promote hepatotoxicity and nephrotoxicity? *Toxicol.* **174 (2)**: 87-95.
- Thang, C.M., Ledin, I. and Bertilsson, J. 2010. Effect of feeding cassava and/or stylosanthes foliage on the performance of crossbred growing cattle. *Trop. Anim. Health Prod.* **42(1)**: 1-11.
- Zagrobelyny, M., Bak, S., Rasmussen, A.V., Jorgensen, B., Naumann, C.M. & Lindberg Moller, B. 2004. Cyanogenic glucosides and plant-insect interactions. *Phytochem.* **65(3)** : 293-306. ■