



# Effect of supplementation of differentially treated banana inflorescence on intestinal morphology in broiler birds<sup>#</sup>

K. Ambili<sup>1</sup>, Deepa Ananth<sup>2\*</sup>, Biju Chacko<sup>3</sup>, S. Senthil Murugan<sup>4</sup>,

H. S. Patki<sup>5</sup>, K. P. Surjith<sup>5</sup>, Abdul Muneer<sup>7</sup> and T. K. Dinsha<sup>1</sup>

Department of Animal Nutrition  
College of Veterinary and Animal Sciences, Pookode, Wayanad – 673 576  
Kerala Veterinary and Animal Sciences University  
Kerala, India

Citation: Ambili, K., Deepa, A., Biju C., Senthil M.S., Patki, H.S., Surjith, K.P., Muneer, A. and Dinsha, T.K. 2023. Effect of supplementation of differentially treated banana inflorescence on intestinal morphology in broiler birds. *J. Vet. Anim. Sci.* **54**(2):396-403

DOI: <https://doi.org/10.51966/jvas.2023.54.2.396-403>

Received: 09.11.2022

Accepted: 07.03.2023

Published: 30.06.2023

## Abstract

A study was conducted on 96 Vencobb 430, day-old broiler chicks to evaluate the effect of steam treatment on banana inflorescence supplementation as prebiotic on intestinal morphology. The birds were randomly assigned into three treatment groups having four replicates with eight birds per replicate and assigned control diet, formulated in accordance with BIS recommendation to control (T1) group and with supplementation of 0.5% dried banana inflorescence (T2 group) or 0.5% steam treated banana inflorescence (T3 group). After 42 days of feeding trial, the live weight was significantly higher in T3 and T2 than control. Two birds from each replicate were sacrificed to study the intestinal morphometry and pH. The weight of intestine varied significantly ( $p < 0.01$ ) between the treatments and was higher in T3 while the per cent of intestinal weight did not differ significantly. Intestinal morphometry revealed that the villus height was significantly ( $p < 0.01$ ) higher in duodenum, jejunum, and caecum in T3 and ileum in T2. The crypt depth was significantly ( $p < 0.01$ ) higher in jejunum, ileum and caeca in T3 and T2 in duodenum. Caecal crypt depth showed significantly ( $p < 0.01$ ) low value in T2. Ileal crypt depth ratio was significantly ( $p < 0.01$ ) higher in T2 while the caecum crypt depth was significantly ( $p < 0.01$ ) high in T3. It is concluded that banana inflorescence influenced the gut morphometry in broilers.

**Keywords:** Banana inflorescence, *Lactobacillus*, histomorphometry

<sup>#</sup> Part of MVSc thesis submitted to Kerala Veterinary and Animal Sciences University, Pookode, Wayanad, Kerala.

1. MVSc Scholar
2. Assistant Professor, Department of Animal Nutrition, College of Veterinary and Animal Sciences Mannuthy
3. Associate Professor and Head
4. Assistant Professor
5. Assistant Professor, Department of Veterinary Anatomy
6. Assistant Professor, Department of Poultry Science

\*Corresponding author: [adeepa@kvasu.ac.in](mailto:adeepa@kvasu.ac.in), Ph.9562775354

Copyright: © 2023 Ambili *et al.* This is an open access article distributed under the terms of the Creative Commons Attribution 4.0 International License (<http://creativecommons.org/licenses/by/4.0/>), which permits unrestricted use, distribution, and reproduction in any medium, provided the original author and source are credited.

Poultry farming is currently one of the fast-growing subsector of livestock industry and the increasing growth necessitates the adoption of feed additives which are cost effective, safe and improve production efficiency. The use of antibiotics as feed additive is often being questioned due to issues regarding antimicrobial resistance and antimicrobial residues in food animals. The use of prebiotics and probiotics are gaining more importance as natural establishment of probiotic organism ensures gut health and improves gut immunity.

Banana is the biggest herbaceous and tropical flowering plant in the family Musaceae and is one of the earliest cultivated plants (Perrier *et al.*, 2011). The male sterile flower of the banana plant is the banana blossom, flower, heart, or bud (Suffi *et al.*, 2021) and found to have health benefits such as the antioxidant and anti-diabetic activities (Lau *et al.*, 2020) and contains numerous distinct bioactive components including phenols, tannins, steroids, glycosides, flavonoids, and saponins (Pushpaveni *et al.*, 2019). Banana inflorescences possess 8.21, 14.50, 4.04, and 20.6 percent protein, fat, ash, and hemicellulose on dry matter basis, respectively. The percentage of total carbohydrates reported was 58.82. Due to their high potassium content (5008.26 mg/100g) and fibre content (49.83%), the dried inflorescences were shown to provide a significant nutritional complement (Fingolo *et al.*, 2012).

The current study aims at understanding the effect of differentially treated banana inflorescence on gut health, intestinal weight and morphometry in poultry broilers.

### Materials and methods

Ninety-six, day old Vencobb 430 broiler chicks were raised under standard farm conditions at Instructional Livestock Farm Complex (ILFC), College of Veterinary

and Animal Sciences, Pookode, Wayanad for the experimental study. All the chicks were wing banded, weighed individually and were randomly distributed into three groups (T1, T2, and T3) with four replicates having eight chicks each. Banana inflorescence (Musa AB) were procured and dried in the oven at 100°C for 42h and powdered. The steam treated inflorescence was prepared by autoclaving the whole banana inflorescence (Musa AB) at 121°C for 20 minutes. The basal diets (broiler pre starter, starter and finisher) were prepared as per BIS (IS 1374: 2007) and fed to T1 as control. For the other groups, the basal diets were supplemented with dried banana inflorescence (T2) or steam treated banana inflorescence (T3) at 5g/kg respectively. The composition of the basal diet (pre-starter, starter and finisher) and levels of supplementation followed in this study are presented in Table 1 & 2.

The birds were reared for 42 days under standard brooding, housing and management practices followed in the farm and were given pre-starter (0-7 days), starter (8-21 days) and finisher (22-42 days) feed and clean drinking water *ad libitum*.

On the 42<sup>nd</sup> day of feeding trial, two birds from each replicate were randomly selected and humanely sacrificed to assess the intestinal weight and histomorphometry. The weight of intestine and pH were assessed in one bird and the histo-morphometric measurements of gut were assessed in the other bird. After slaughter, the bird intestine was collected, weighed and flushed slowly with normal saline to remove any feed that may be present in the intestine and was placed in 10 % neutral buffer formalin for 7 days. After seven days the 0.5 cm long tissue was cut from duodenum, jejunum, ileum and caecum, placed in cassette and processed by standard tissue processing protocols (Luna, 1968). Sections were taken at 5µm thickness by using semi-automatic M-TECH microtome. Haematoxylin and Eosin staining method

**Table 1.** Level of supplementation of feed

Treatment Group	Experimental Diet
T1	Basal diet (BD)
T2	BD + dried banana inflorescence (5 g/ kg)
T3	BD + steam treated banana inflorescence (5g/kg)

**Table 2.** Ingredient composition of broiler pre-starter, starter and finisher feed (%)

Ingredients	Pre-Starter			Starter			Finisher		
	T1	T2	T3	T1	T2	T3	T1	T2	T3
Maize	53.0	53.0	53.0	55.40	55.40	55.40	58.80	58.80	58.80
SBM	39.80	39.80	39.80	37.0	37.0	37.0	32.0	32.0	32.0
DCP	2.35	2.35	2.35	2.35	2.35	2.35	2.35	2.35	2.35
Calcite	0.5	0.5	0.5	0.5	0.5	0.5	0.7	0.7	0.7
Salt	0.45	0.45	0.45	0.45	0.45	0.45	0.45	0.45	0.45
Sunflower oil	3.90	3.90	3.90	4.30	4.30	4.30	5.7	5.7	5.7
<b>Total</b>	<b>100</b>	<b>100</b>	<b>100</b>	<b>100</b>	<b>100</b>	<b>100</b>	<b>100</b>	<b>100</b>	<b>100</b>
Trace mineral mixture (%)	0.1	0.1	0.1	0.1	0.1	0.1	0.10	0.10	0.10
Vitamin premix (%)	0.05	0.05	0.05	0.05	0.05	0.05	0.05	0.05	0.05
Lysine (%)	0.20	0.20	0.20	0.16	0.16	0.16	0.08	0.08	0.08
Methionine (%)	0.18	0.18	0.18	0.18	0.18	0.18	0.17	0.17	0.17
Choline (%)	0.1	0.1	0.1	0.1	0.1	0.1	0.1	0.1	0.1
Toxin binder (%)	0.1	0.1	0.1	0.1	0.1	0.1	0.1	0.1	0.1
Liver Powder (%)	0.05	0.05	0.05	0.05	0.05	0.05	0.05	0.05	0.05
Coccidiostat (%)	0.05	0.05	0.05	0.05	0.05	0.05	0.05	0.05	0.05
Dried banana inflorescence (%)	0.00	0.5	0.00	0.00	0.5	0.00	0.00	0.5	0.00
Steam treated banana inflorescence (%)	0.00	0.00	0.5	0.00	0.00	0.5	0.00	0.00	0.5
<b>Calculated Analytical Values</b>									
Metabolizable energy (Kcal/kg)	3070	3070	3070	3120	3120	3120	3240	3240	3240
Crude Protein (%)	23.13	23.13	23.13	22.06	22.06	22.06	20.07	20.07	20.07
Calcium (%)	1.00	1.00	1.00	0.99	0.99	0.98	0.98	0.98	0.98
Available Phosphorus (%)	0.88	0.88	0.88	0.87	0.87	0.84	0.84	0.84	0.84

was used for histological studies. The histomorphometric measurements were taken at 40X magnification for intestinal villus and crypt depth using image analysing software (Micaps Microview).

## Result and discussion

At the end of the 42-day trial, the live weight obtained among the three groups were  $1533.5 \pm 18.79$ ,  $1659.38 \pm 7.8$  and  $1711.63 \pm 20.9$  g, respectively. The live weight, intestinal weight, per cent of intestine and the pH of ileum and caecum are given in Table 3. The group supplemented with steamed banana inflorescence and dried banana inflorescence showed significant ( $p < 0.01$ ) increase in live weight. The per cent carcass yield obtained in the three treatment groups were  $70.42 \pm 0.18$ ,  $71.7 \pm 0.15$ ,  $71.81 \pm 18$ , respectively, also varied significantly ( $p < 0.01$ ) with the treatments and the highest carcass yield recorded was with the steam treated banana inflorescence supplemented group. The observations were found to be similar to the dressing per cent of

70.47, 70.90 and 72.28 reported by Waqas *et al.* (2018) with the supplementation of mannan oligosaccharide (Actigen™) at 0.2, 0.4, 0.6 g/kg, respectively when compared to the control (69.91 %). In contrast to our findings, Shajini *et al.* (2022) reported supplementation of chitosan at 30g/kg to birds did not have any significant effect on dressing percentage.

The weight of intestine were  $141.88 \pm 6.37$ ,  $178.75 \pm 8.36$  and  $175 \pm 7.84$  grams respectively, found to be significantly ( $p < 0.001$ ) increased with the supplementation, while the per cent of intestine with respect to carcass weight were  $14.3 \pm 0.007$ ,  $15 \pm 0.006$  and  $14 \pm 0.007$  respectively, were found to be similar among the treatment groups. Wang *et al.* (2016) also reported no difference in per cent intestine (2.622) on supplementation of prebiotic (mannan oligosaccharide) when compared to control (2.521).

The pH values in ileum and caecum of three treatment groups were  $6.18 \pm 0.21$ ,  $6.44 \pm 0.26$ ,  $6.39 \pm 0.04$  and  $6.83 \pm 0.21$ ,  $6.71$

$\pm 0.32$ ,  $6.87 \pm 0.12$  respectively (Table 3) and values did not vary significantly. The findings of present study were similar to Houshmand *et al.* (2011) who reported that the feeding of prebiotic feed did not affect the pH of ileum (6.63) and caecum (6.93) of birds.

The intestinal villi continuously adjust as a response to conditions in the lumen of the intestine (that is influenced by composition of diet) reflecting the dynamic environment inside the intestine of animals. Accordingly, longer intestinal villi are associated with an increase in the absorptive surface of the intestines as well as increased absorption capacity (Izadi *et al.*, 2013). Analysis of intestinal morphometry revealed a significant increment in villus height in all banana inflorescence supplemented groups. This increment indicated an increase in intestinal surface area and absorptive strength. The villus height of duodenum was significantly

high ( $p < 0.001$ ) in T3 ( $1567.73 \pm 30.81$ ) while the crypt depth was significantly higher in T2 ( $483.37 \pm 35.51$ ) than the control (Fig.1). There was also significant increase in duodenal crypt depth ratio in banana inflorescence supplemented group suggestive of increased lactic acid bacteria (Nguyen *et al.*, 2021). Pelicano *et al.* (2005) reported a lower ( $p < 0.01$ ) villus height in the duodenum of birds fed diets with prebiotics ( $1401 \mu\text{m}$ ) than control ( $1539 \mu\text{m}$ ). Similar observations with improved villus height, crypt depth and villus-to-crypt ratio of duodenum were made by Eyng *et al.* (2014) in birds that were fed bee pollen or propolis and Supriya *et al.* (2022) in birds fed with probiotics and organic acids.

The jejunal villus height and crypt depth showed significant difference ( $p < 0.001$ ) among the treatments and were highest in T3 ( $1286.79 \pm 29.8 \mu\text{m}$ ,  $499.17 \pm 29.16 \mu\text{m}$ ) followed by T2

**Table 3.** Live weight, intestinal weight, per cent of intestine weight and the pH of ileum and caecum

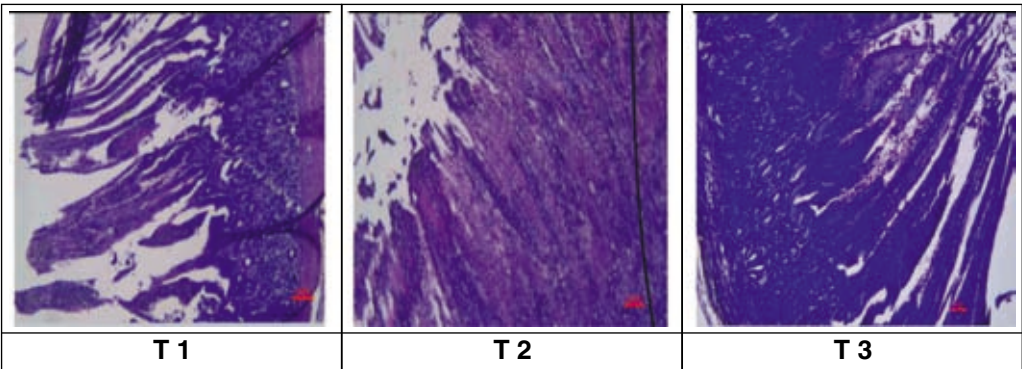
Attributes	T1	T2	T3	(p-value)
Live weight	$1533.5 \pm 18.79^b$	$1659.38 \pm 7.8^a$	$1711.63 \pm 20.9^a$	$<0.001^{**}$
Carcass yield (%)	$70.42 \pm 0.18^b$	$71.7 \pm 0.15^{ab}$	$71.81 \pm 18^a$	$<0.001^{**}$
Intestinal weight	$141.88 \pm 6.37^b$	$178.75 \pm 8.36^a$	$175 \pm 7.84^a$	$<0.001^{**}$
Percent of Intestine	$14.30 \pm 0.007$	$14.88 \pm 0.006$	$13.49 \pm 0.007$	$0.328^{ns}$
pH of Ileum	$6.18 \pm 0.21$	$6.44 \pm 0.26$	$6.39 \pm 0.04$	$0.057^{ns}$
pH of Caecum	$6.83 \pm 0.21$	$6.71 \pm 0.32$	$6.87 \pm 0.12$	$0.968^{ns}$

**\*\* Significant at 0.01 level; ns non-significant: Means having different letter as superscript differ significantly within a row**

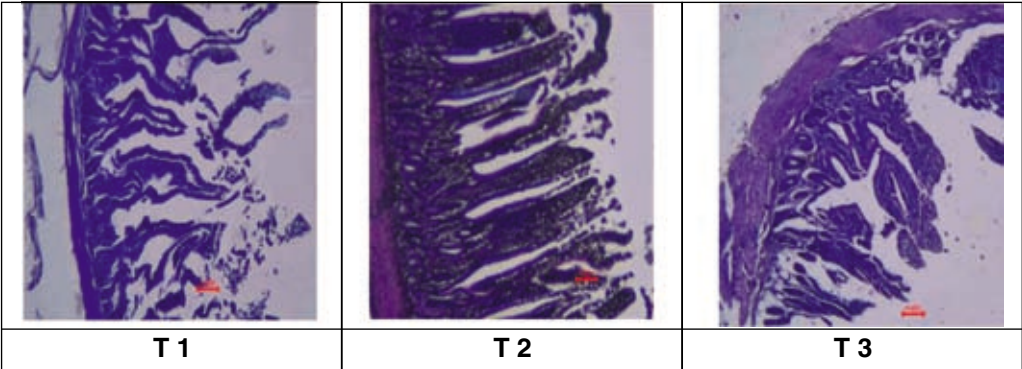
**Table 4.** Gut histo-morphometric measurements of gut

Variables	T1	T2	T3	(p-value)
Duodenum Villus Height ( $\mu\text{m}$ )	$1261.32 \pm 9.03^b$	$1441.78 \pm 58.67^{ab}$	$1567.73 \pm 30.81^a$	$<0.001^{**}$
Duodenum Crypt Depth ( $\mu\text{m}$ )	$440.87 \pm 8.26^b$	$483.37 \pm 35.51^a$	$461.99 \pm 25.04^{ab}$	$0.394$
Duodenum Crypt Depth Ratio	$2.866 \pm 0.52^b$	$3.04 \pm 0.17^{ab}$	$3.44 \pm 0.16^a$	$0.002^*$
Jejunum Villus Height ( $\mu\text{m}$ )	$539.66 \pm 27.58^c$	$1006.85 \pm 27.46^b$	$1286.79 \pm 29.8^a$	$<0.001^{**}$
Jejunum Crypt Depth ( $\mu\text{m}$ )	$161.59 \pm 3.7^c$	$316.08 \pm 10.76^b$	$499.17 \pm 29.16^a$	$<0.001^{**}$
Jejunum Crypt Depth Ratio	$3.33 \pm 0.13^b$	$3.19 \pm 0.09^c$	$3.44 \pm 0.21^a$	$<0.001^{**}$
Ileum Villus Height ( $\mu\text{m}$ )	$630.8 \pm 32.65^c$	$986.49 \pm 15.51^a$	$738.9 \pm 28.37^b$	$<0.001^{**}$
Ileum Crypt Depth ( $\mu\text{m}$ )	$174.51 \pm 2.42^c$	$219.41 \pm 8.18^b$	$313.97 \pm 20.08^a$	$<0.001^{**}$
Ileum Crypt Depth Ratio	$3.616 \pm 0.15^b$	$4.51 \pm 0.11^a$	$2.338 \pm 0.12^c$	$<0.001^{**}$
Caecum Villus Height ( $\mu\text{m}$ )	$559.08 \pm 26.01^b$	$370.81 \pm 9.05^c$	$1124.35 \pm 19.66^a$	$<0.001^{**}$
Caecum Crypt Depth ( $\mu\text{m}$ )	$125.91 \pm 3.87^{ab}$	$94.42 \pm 5.36^b$	$135.88 \pm 21.64^a$	$<0.001^{**}$
Caecum Crypt Depth Ratio	$4.44 \pm 0.16^b$	$3.98 \pm 0.18^c$	$9.02 \pm 0.84^a$	$0.001^{**}$

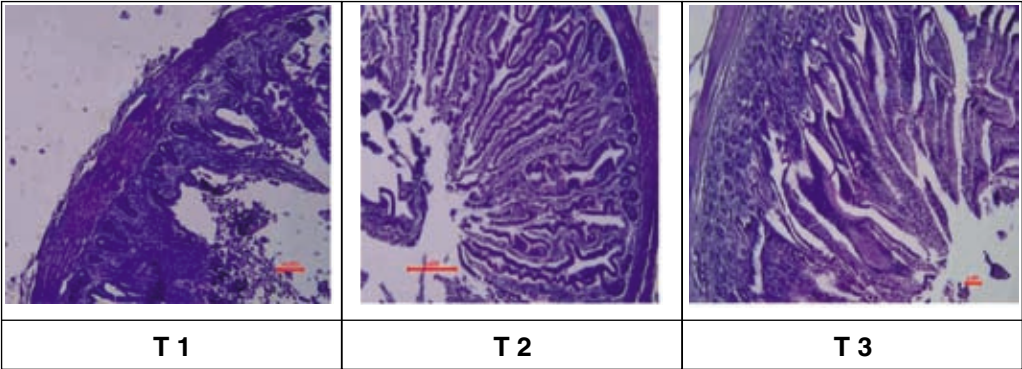
**\*\* Significant at 0.01 level; ns non-significant Means having different superscript differ significantly within a row**



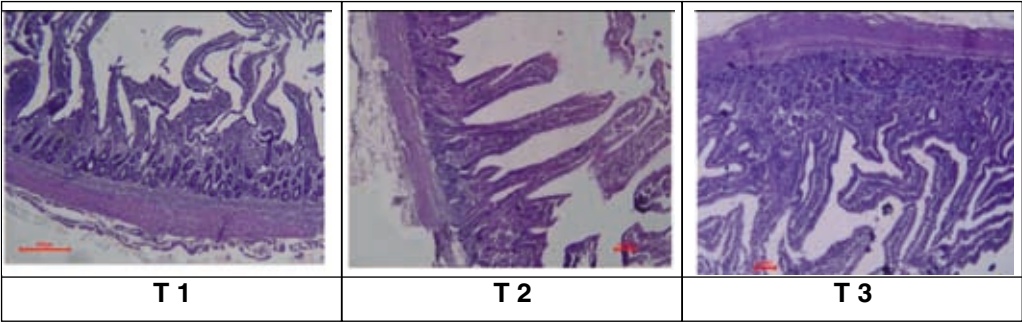
**Fig.1.** Cross-section of duodenum of three treatment groups (H & E x 40)



**Fig.2.** Cross-section of jejunum of three treatment groups (H & E x 40)



**Fig.3.** Cross-section of ileum of three treatment groups (H & E x 40)



**Fig.4.** Cross-section of caecum of three treatment groups (H & E x 40)

Effect of supplementation of differentially treated Banana Inflorescence on Intestinal Morphology in Broiler Birds

(1006.85 ± 27.46 µm, 316.08 ± 10.76 µm) over the control T1 (539.66 ± 27.58 µm, 161.59 ± 3.7 µm) the villus height to crypt depth ratio also differed among the treatment groups (Fig.2). Pelicano *et al.* (2005) also observed higher villi in the jejunum ( $p < 0.01$ ) on supplementation of MOS-based prebiotics (1243 µm) than the diets without prebiotics. Similar observation was also reported by Baurhoo *et al.* (2007) on feeding of purified lignin at 1.25% and 2.5% and mannan oligosaccharides MOS at 0.1%, showed higher jejunum villi length (2627 µm and 2290 µm respectively) compared to control (2114 µm).

The ileum is thought to play a role as a site for water and mineral absorption, although some digestion and absorption of fat, protein and starch may occur. The ileal villus height was found to be significantly ( $p < 0.001$ ) high in T2 (986.49 ± 15.51 µm) and T3 (738.9 ± 28.37 µm) compared to control (630.8 ± 32.65 µm) while the crypt depth showed significantly higher ( $p < 0.001$ ) in T3 (313.97 ± 20.08 µm) and in T2 (219.41 ± 8.18 µm) compared to control (174.51 ± 2.42 µm) (Fig.3). Al-Baadani *et al.* (2016) also reported higher length of villi in ileum and jejunum (527.94 µm and 643.89 µm) on dietary inclusion of prebiotics in *Cl. perfringens* challenged broiler chickens (353.10 µm and 432.10 µm). The crypt depth ratio was significantly high in T2 (4.51 ± 0.11), while it was significantly low in T3 (2.338 ± 0.12) compared to control (3.616 ± 0.15). The increased V:C ratio could result in the increase in intestinal score (Nguyen *et al.*, 2021). Santin *et al.*, (2001) reported significant increase in villus height in duodenum, jejunum and ileum (1040 µm, 496 µm, 422 µm respectively) when compared to control (856 µm, 342 µm, 325 µm respectively) on supplementation of *Saccharomyces cerevisiae* cell wall at 0.1% and 0.2% to broiler birds.

The caecal villus height showed significant difference ( $p < 0.001$ ) among the treatments and were highest in T3 (1124.35 µm) when compared to control (559.08 µm) and T2 (370.81 µm). Tsirtsikos *et al.* (2012) also observed significant increase in villus height (249, 223, 272) in caecum when compared to control (204) when supplemented with probiotic, *Lactobacillus reuteri* at  $10^8$ ,  $10^9$ ,  $10^{10}$

colony forming units of probiotic/kg. According to Iji and Tivey (1998), the increase in villus height and crypt depth may be due increase in bacterial colonisation which increase the fermentation rate and absorption of nutrients.

## Conclusion

In the present study, supplementation of banana inflorescence in dried or steam treated forms, the dried form at 0.5 percent level in broiler diet could significantly increase the live weight in broiler diet and the histomorphometric parameters in gut significantly varied with the control. Birds having steam treated banana inflorescence supplementation, showed increased villus height of duodenum, jejunum and caecum and increased crypt depth in jejunum, ileum and caecum as well as duodenal and caecal villus to crypt depth ratio, while treatment with dried banana inflorescence showed highest duodenal crypt depth, ileal villus height and crypt depth ratio which could help in better nutrient absorption and growth in broiler birds.

## Acknowledgements

We are grateful to Kerala Veterinary and Animal Sciences University for providing facilities for carrying out our research.

## Conflict of interest

The authors declare that they have no conflict of interest

## References

- Al-Baadani, H.H., Abudabos, A.M., Al-Mufarrej, S.I. and Alzawqari, M. 2016. Effects of dietary inclusion of probiotics, prebiotics and synbiotics on intestinal histological changes in challenged broiler chickens. *S. Afr. J. Anim. Sci.* **46**:157-165.
- Baurhoo, B., Phillip, L. and Ruiz-Feria, C.A. 2007. Effects of purified lignin and mannan oligosaccharides on intestinal integrity and microbial populations in the ceca and litter of broiler chickens. *Poult. Sci.* **86**: 1070-1078.

- Eyng, C., Murakami, A.E., Duarte, C.R.A. and Santos, T.C. 2014. Effect of dietary supplementation with an ethanolic extract of propolis on broiler intestinal morphology and digestive enzyme activity. *J. Anim. Physiol. Anim. Nutr.* **98**: 393-401.
- Fingolo, C.E., Braga, J., Vieira, A., Moura, M.R. and Kaplan, M.A.C. 2012. The natural impact of banana inflorescences (*Musa acuminata*) on human nutrition. *An. Acad. Bras. Cienc.* **84**: 891-898
- Houshmand, M., Azhar, K., Zulkifli, I., Bejo, M.H. and Kamyab, A. 2011. Effects of nonantibiotic feed additives on performance, nutrient retention, gut pH, and intestinal morphology of broilers fed different levels of energy. *J. Appl. Poult. Res.* **20**: 121-128.
- Lau, B.F., Kong, K.W., Leong, K.H., Sun, J., He, X., Wang, Z., Mustafa, M.R., Ling, T.C., Ismail, A. (2020). Banana inflorescence: Its bio-prospects as an ingredient for functional foods. *Trends. Food Sci. Technol.* **97**: 14-28.
- Luna, L.G. 1968. *Manual of histologic staining methods of the Armed Forces Institute of Pathology*. (3rd Ed). McGraw-Hill, New York.
- Iji, P.A. and Tivey, D.R. 1998. Natural and synthetic oligosaccharides in broiler chicken diets. *Worlds Poult. Sci. J.* **54**: 129-143.
- Izadi, H., Arshami, J., Golian, A. and Reza Raji, M. 2013. Effects of chicory root powder on growth performance and histomorphometry of jejunum in broiler chicks. *Vet. Res. Forum.* **4**: 169-174
- Nguyen, D.T., Le, N.H., Pham, V.V., Eva, P., Alberto, F. and Le, H.T., Relationship between ratio of villous height: crypt depth and gut bacteria counts as well as production parameters in broiler chickens. *J. Agric. Dev.* **20**: 1-10.
- Pelicano, E.R.L., Souza, P.D., Souza, H.D., Figueiredo, D.F., Boiago, M.M., Carvalho, S.R. and Bordon, V.F. 2005. Intestinal mucosa development in broiler chickens fed natural growth promoters. *Brazilian J. Poult. Sci.* **7**: 221-229.
- Perrier, X., De Langhe, E., Donohue, M., Lentfer, C., Vrydaghs, L., Bakry, F., Carreel, F., Hippolyte, I., Horry, J.P., Jenny, C. and Lebot, V. 2011. Multidisciplinary perspectives on banana (*Musa* spp.) domestication. *Proc. Natl. Acad. Sci.* **108**: 11311-11318
- Pushpaveni, C., Visagaperumal D. and C. Vineeth. 2019. A Review on Banana Blossom: The Heart of Banana. *J. Pharm. Pharmacogn. Res.* **8**: 440-450.
- Santin, E., Maiorka, A., Macari, M., Grecco, M., Sanchez, J.C., Okada, T.M. and Myasaka, A.M. 2001. Performance and intestinal mucosa development of broiler chickens fed diets containing *Saccharomyces cerevisiae* cell wall. *J. Appl. Poult. Res.* **10**: 236-244
- Shajini, S., Beena C. Joseph, Anitha, P., Harikrishnan S. and Sajith Purushothaman. 2022. Effect of chitosan and L-carnitine supplementation on carcass characteristics of broiler chicken. *J. Vet. Anim. Sci.* **53**: 413-416
- Suffi, N.S.M., Mohamed, E., Camalxaman, S.N., Rambely, A.S. and Haron, N. 2021. The medicinal benefits, phytochemical constituents and antioxidant properties of banana blossom: A mini review. *Healthscope.* **4**: 113-118.
- Supriya, R., Chacko, B., Anitha, P., Suja, C. S. and Priya, P. M. 2022. Effects of fermented soybean meal, probiotics and organic acids on intestinal morphology, pH and microbial count in broilers. *J. Vet. Anim. Sci.* **53**: 348-355.
- Tsirtsikos, P., Fegeros, K., Balaskas, C., Kominakis, A. and Mountzouris, K.C., 2012. Dietary probiotic inclusion level modulates intestinal mucin composition and mucosal morphology in broilers. *Poult. Sci.* **91**: 1860-1868.

- Wang, X., Farnell, Y.Z., Peebles, E.D., Kiess, A.S., Wamsley, K.G.S. and Zhai, W. 2016. Effects of prebiotics, probiotics, and their combination on growth performance, small intestine morphology, and resident *Lactobacillus* of male broilers. *Poult Sci.* **95**: 1332-1340.
- Waqas, M., Mehmood, S., Mahmud, A., Hussain, J., Ahmad, S., Khan, M.T., Rehman, A., Zia, M.W. and Shaheen, M.S. 2019. Effect of yeast based mannan oligosaccharide (Actigen™) supplementation on growth, carcass characteristics and physiological response in broiler chickens. *Indian J. Anim. Res.* **53**: 1475-1479. ■