



EXPERIMENTAL CARCINOGENICITY STUDIES OF N-NITROSOMETHYLUREA IN RATS*

Mammen J. Abraham¹ and
A. Sundararaj²

Department of Pathology
Madras Veterinary College
Vepery, Chennai – 600 007.

Received - 30.08.09
Accepted - 25.04.11

Abstract

The object of this study was to assess the tumour promoting potential of Phenobarbital (PB) after initiation with N-Nitrosomethylurea (NMU). In the NMU group, hepatocytes showed mild toxic changes. The kidney manifested degenerative changes. There were squamous cell hyperplastic changes in the stomach. In the NMU + PB group, the liver showed toxic changes like vacuolation, granularity and necrosis of hepatocytes as well as preneoplastic changes like clear cell foci and focal hepatocellular dysplasia. Ultrastructurally the nuclei of hepatic cells showed an increase in interchromation granules. Besides, numerous vacuoles were also seen in the cytoplasm which could be due to dilatation and vesiculation of RER and SER due to ingress of water. The other changes included hyperaemia and tubular degeneration in the kidney, perivascular collection of mononuclear cells in the lungs, mild gliosis with focal proliferation of meningeal cells in the brain. In the testes, there were necrosis of spermatids and accumulation of debris in the seminiferous tubules. Mammary gland showed adenoma tous hyperplasia. The changes in the urinary bladder mucosa varied from marked epithelial proliferation to papillomatous foldings.

Keywords: Phenobarbital, N-Nitrosomethyl urea

N-Nitrosomethylurea (NMU) which belongs to the N-nitroso group of chemical compounds have been found in low quantities in the human environment and may also be formed from precursors in the human body. It is a very potent resorptive carcinogen which can induce tumour formation in several organs in many species of animals (Talcott *et al.*, 1990).

Phenobarbital is a mitogen and potent tumour promoter which could exert tumour promotion effect on a pre-existing dormant tumorigenic lesion. (Rolf Schutle-Hermann, *et al.*, 1981). An experimental study was undertaken with the objective of assessing the modifying effects of the tumour promoter, phenobarbital on the multiorgan carcinogenesis subsequent to initiation by NMU.

Materials and Methods

Three groups of rats, each group comprising 30 male rats and 10 female rats were randomly selected. One group of rats were maintained as untreated control group, the second group was administered four doses of NMU at a dosage rate of 25 mg/ kg body weight intraperitoneally at 0,4,8 and 12 days. The third group was administered four initiating doses of NMU at the rate of 25 mg/ kg. body weight intraperitoneally at 0,4, 8 and 12 days followed by daily administration of phenobarbital at the level of 0.05% in the basal

*Part of Ph.D. thesis submitted by the first author to TANUVAS, Chennai-63

¹Associate Professor, CVAS, Mannuthy

²Professor and Head (Retd.)

diet. All the groups of experimental rats were maintained for a period of 20 weeks and all the surviving rats were sacrificed and subjected to detailed gross pathology, histopathology and EM Studies.

Results and Discussion

In the NMU group the liver showed mild toxic changes which included granularity of the hepatocytes, mild portal infiltration and occasional venous stasis. Since these groups of animals were sacrificed nearly 10 weeks after the discontinuation of NMU administration, the above observed changes could be indicative of recovery from toxic effects of NMU as observed by Frei (1970). The lungs showed focal collection of mononuclear cells while the stomach showed squamous cell hyperplasia. The mucosa of the urinary bladder showed epithelial hyperplasia that formed papilliferous folds (Fig.1). Normally the urinary bladder has a low mitotic index. In this case the persistence of the hyperplastic changes could be suggestive of a tendency towards neoplastic

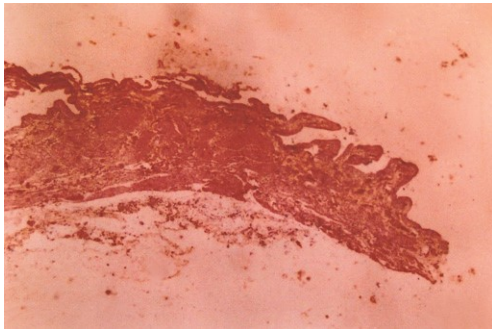


Fig.1. NMU group - Mucosa of the urinary bladder showing epithelial hyperplasia forming papilliferous folds

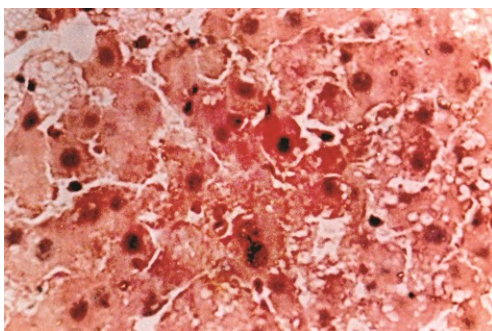


Fig. 2. NMU + PB group - Liver section showing focal hepatocytes dysplasia characterised by individualisation, hepatocytomegaly and karyomegaly

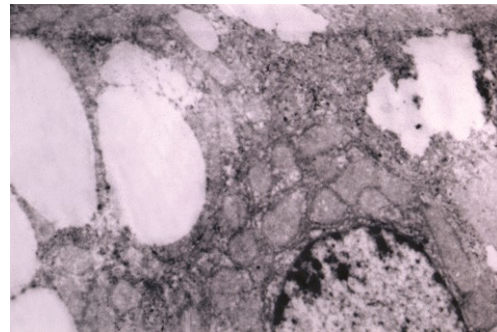


Fig. 3. Ultrastructure of hepatocytes showing cytocavities and electron dense cytosol

transformation. A single cytotoxic dose of NMU (2.0 mg) administered intravesicularly produced reversible hyperplasia of the bladder epithelium (Hicks and Wakefield, 1972).

The kidneys showed primarily diffuse hyperaemia and degenerative changes in the tubular epithelial cells. Though NMU has been shown to produce extensive methylation of nuclei acids in the kidneys (Swann and Magee, 1968) this had no association with any significant toxic change in the kidney.

In the NMU + PB group of this study, the liver showed toxic changes characterised by vacuolation of the hepatocytes, granularity and necrosis. Besides, there were preneoplastic changes in the form of focal hepatocellular dysplasia characterised by individualisation of hepatocytes, hepato cytomegaly and karyomegaly (Fig.2). Ultrastructurally there was an increase of interchromatin granules and this alteration could represent alternate sites for the synthesis of RNA since the toxicity of NMU and phenobarbital could inhibit nucleolar RNA synthesis (Svoboda and Higginson, 1968). Moreover cytocavities could also be seen which could be due to the dilatation and vesiculation of the RER as well as that of the proliferated SER, following the ingress of water (Fig.3).The vesicles produced by fragmentation of RER in hepatocytes are usually sparsely populated by ribosomes which could be due to degranulation of RER and the involvement of SER and Golgi complex in vesicle formation.

The other prominent changes included hyperaemia and tubular cell degeneration in the kidneys, focal proliferation of ependymal cells in the brain, focal squamous cell hyperplasia and papillomatous growths in the stomach.

In the testes, there were necrosis of spermatids and accumulation of debris in the seminiferous tubules. Mammary glands showed adenomatous hyperplasia. The changes in the urinary bladder mucosa varied from marked epithelial proliferation to papillomatous foldings.

The stimulatory effect of phenobarbital on the oxidized lipids, proliferative activity, kinetics of DNA synthesis and cell cycle time alteration in the liver may be the mechanisms by which the non-genotoxic mitogen induces its carcinogenic action (El-Sokkary, 2007). Phenobarbital is a liver mitogen which when administered for several months to rats, pretreated with a carcinogen was shown to result in an increase in the size and number of preneoplastic islands in the liver (Pitot *et al.*, 1978). The appearance of liver tumours in the mitogen-treated animals resulted from promotion of a pre-existing dormant tumorigenic lesion of genetic or environmental origin. As with partial hepatectomy the main activity of mitogen, like phenobarbital was to stimulate DNA synthesis (Rolf-Schulte – Hermann *et al.*, 1981).

References

- El-Sokkary, G.H. 2007. An autoradiographic study of cellular proliferation, DNA synthesis and cell cycle variability in the rat liver caused by phenobarbital-induced oxidative stress: the protective role of melatonin. *Cell Mol. Biol. Lett.*, **12** : 317-330.
- Frei, J. V. 1970. Toxicity, tissue changes and tumor induction in inbred swiss mice by methyl nitrosamine and amide compounds. *Cancer Res.*, **30**:11-17.
- Hicks, R. M. and Wakefield, J. S .J. 1972. Rapid induction of bladder cancer in rats with N-Methyl-N-Nitrosourea. *Histology, Chem. Biol. Interact.*, **5**:139.
- Pitot, H.C., Barnes, L. Goldworthy, T. and Kitagawa, T. 1978. Biochemical characterization of stage of hepatocarcinogenesis after a single dose of diethyl nitrosamine. *Nature*, **271**:456-458.
- Rolf Schulte – Hermann, G., Ohde, J., Schuppler I. and Timmermann, T. 1981. Enhanced proliferation of putative preneoplastic cells in rat liver following treatment with the tumour promoters Phenobarbital, hexachlorocyclohexane, steroid compounds and nafenopin. *Cancer Res.*, **41**:2556-2562.
- Svoboda. R. and Higginson, J. 1968. Comparison of ultrastructural changes in rat liver due to chemical carcinogens. *Cancer Res.*, **28**:1703-1733.
- Swann, P. F. and Magee, V. 1968. Nitrosamine-induced carcinogenesis: The alkylation of nucleic acids of the rat by N-Methyl-N-Nitrosourea, dimethyl nitrosamine, dimethyl sulphate and methyl methane sulphonate. *Biochem. J.*, **110**:39-47.

