



GRANULOMA FORMING INTESTINAL SCHISTOSOMOSIS IN BUFFALOES

K.Vinodkumar¹, P.V.Tresamol²,
K. Devada³ and K.Vijayakumar⁴

Department of Veterinary Epidemiology and Preventive Medicine
College of Veterinary and Animal Sciences,
Mannuthy - 680 651, Thrissur, Kerala

Received - 12.09.11

Accepted - 24.10.11

Abstract

Characteristic observations of Schistosoma spindale infection among two large herds of male buffalo calves are reported. Clinical symptoms included anorexia and cachexia leading to heavy mortality. Extensive nodular changes on the mucosa of small intestine were observed during post mortem examination which revealed multiple ova of S.spindale surrounded with diffuse infiltration of lymphocytes and plasma cells. A few cases had fibroblasts, histiocytes and foreign body giant cells. Gross or microscopical lesions were not detected in the liver. Therapy with potassium antimony tartrate at 1.25mg/kg body weight intravenously produced clinical recovery. Etiopathology is discussed.

Keywords: *Schistosoma spindale, buffaloes intestine, granuloma.*

Infections due to *Schistosoma spindale* among cattle are encountered in Kerala as sporadic cases. According to Vaithyanathan (1949) and Mohanty *et al.*(1984), visceral schistosomosis caused by *S.spindale* is characterised by frequent diarrhea with blood and mucus, colic, weight loss and weakness. This disease is generally chronic in nature and symptoms in animals are insufficient to distinguish it from other debilitating infections (De Bont and Vercruyssen, 1998). Verma and Vyas (2004)

reported hepatic lesions in affected buffaloes as moderate with periportal cell infiltration and periportal epithelioid cell granulomas within perilobular zones. Granulomas in intestine of ruminants affected with *S.spindale* were unusual findings. This report deals with a major and characteristic occurrence of *S.spindale* infection among male buffalo calves reared for fattening purpose.

Materials and Methods

Two farms with a total herd size of 126 male buffalo calves (6 to 7 month old) being reared for fattening purpose were affected with amphistomosis. The first farm was by the catchment area of a dam in hill tract region whereas the second farm was by a water logged area in the plains. The calves had been purchased from Pollachi in Tamil Nadu state and brought to the farms two months before. Heavy mortality without any apparent precipitating cause was reported at first. Reduction in feed intake, lethargy and subsequent debility were the other signs observed by the management. Thorough clinical examination, coprological examination and haematological investigation of affected calves were carried out.

Results and Discussion

On clinical examination, animals were found to be very weak and emaciated.

1. Assistant Professor

2. Associate Professor

3. Professor and Head, Dept. of Veterinary Parasitology

4. Associate Professor (On deputation as Joint Commissioner, AH, Govt. of India)

Some had mucopurulent discharge from the eyes. Pyrexia (104°F), anorexia, anaemia (Hb 3.6-4.9 g%), reluctance to graze, dyspnoea and paste-like feces were the primary clinical symptoms. The calves were regularly dewormed using benzimidazole anthelmintics. Repeated examinations of dung did not reveal ova of any parasite. Examination of blood smear by Giemsa staining revealed presence of *Anaplasma marginale* in one calf. No significant changes other than low haemoglobin level were observed in haemograms. Change in the diet, antimicrobial therapy and supportive treatment did not bring about any desirable results. All the twenty eight affected calves died within a period of one month from the onset of symptoms.

Post mortem examination of six calves revealed necrotic areas and pin head sized nodules on the mucosa throughout the intestine visible by gross examination of the surface of intact organ (Fig.1). These nodules were surrounded by bluish, necrotic areas (Fig. 2) and were unevenly spaced without any inflammatory changes in surrounding areas of mucosa. Direct microscopical examination of the section of such nodules revealed numerous ova of *S. spindale* with parts or whole of the miracidia inside. One calf had erosions and ulcers in the distal segments of small intestine (Fig. 3). Other lesions in vital organs included moderate inflammatory changes in the lung and compensatory cardiomegaly. Liver did not present lesions of diagnostic significance in any of the cases. Histopathological examination of posterior parts of small intestine revealed necrosis of the mucosa with dense diffuse infiltration by lymphocytes and plasma cells. The granulomas consisted of the typical spindle shaped ova with degenerated miracidium in the centre surrounded large histiocytes, foreign bodies, giant cells and fibroblasts. Adjacent serosal layer also showed extensive necrosis and infiltration (Fig. 4).

All the animals were administered potassium antimony tartarate (tartar emetic) @1.25mg/kg body weight intravenously in 20 ml distilled water three times on alternate days. Supportive therapy included parenteral antibiotics, crystalloids and vitamins. Grazing on water logged areas was stopped. Mortality continued for one more week, after which no more calves succumbed. Marked improvement was noticed in appetite and general health of the calves.

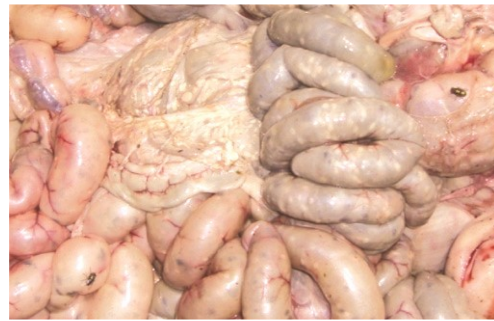

Fig.1 Gross lesions on surface of small intestine



Fig.2 Nodules on intestinal mucosa

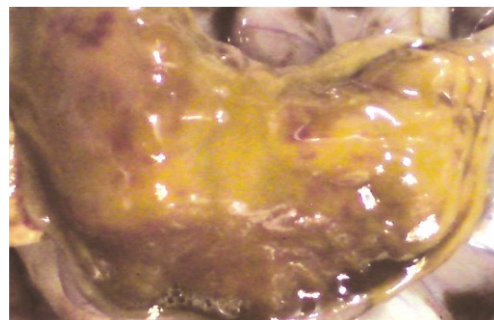

Fig.3 Haemorrhagic tracts on intestinal mucosa

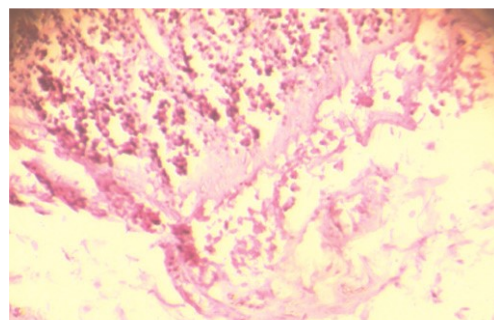


Fig.4. Inflammatory changes in serosa of small intestine 400X

Chronic nature of the lesions and the short interval between arrival of the animals in the farms and manifestation of clinical symptoms points to acquisition of the infection prior to purchase of calves. Obscure nature

of the clinical symptoms and failure to detect ova in faecal samples of any of the animals could be explained by the chronic nature of the infection. *Schistosoma spindale* infection in buffaloes is usually sub-clinically manifested.

Most of the ova of *S. spindale* in buffaloes were entrapped within the basement membrane or embedded in various tissues without being released into the lumen. Intense inflammatory reaction caused by such ova occasionally lead to the formation of nodules. Impaired absorption of nutrients from the affected gastro-intestinal tract lead to emaciation. As migration and subsequent formation of haemorrhagic tracts do not take place, typical clinical symptoms were not manifested in these cases.

Potassium antimony tartrate still remains the drug of choice on account of efficacy and economy. The dose rate of 1-1.5g/

kg bwt daily, for three administrations on alternate days have produced satisfactory results in this instance also.

References

- De Bont, J. and Vercruyse. J. 1998. Schistosomiasis in cattle. *Advances in Parasitology*, **41**:285-363.
- Mohanthy, D.N., Mohanthy, R.K., Ray, S.K. and Mohanthy, K.M. 1984. A note on *Schistosoma spindale* infection in cattle and its successful treatment. *Livestock Advisor*, **9**:37-39.
- Vaidyanathan, S.N. 1949. *Schistosoma spindale* in a cow. Treatment with anthiomaline. *Indian Vet. J.* **26**:225-228.
- Verma, Y. and Vyas, U.K. 2004. Pathology of hepatic schistosomosis in buffaloes (*Bubalis bubalis*). *Indian J. Vet. Path.*, **28**:412-414.

