



# HEPATOPROTECTIVE EFFECT OF TRIPHALA IN AFLATOXICOSIS\*

K. Indu<sup>1</sup> and C.R. Lalithakunjamma<sup>2</sup>

Department of Veterinary Pathology  
College of Veterinary and Animal Sciences  
Mannuthy- 680 651, Thrissur, Kerala

Received - 25.07.11

Accepted - 10.09.11

## Abstract

The objective of this research work was to understand the pathological effects of aflatoxin in rabbits and its counteraction using the herbal formulation Triphala. The study was conducted for a period of two months with twenty four rabbits divided into three groups of eight each. It was evident from the study that the herbal drug triphala could effectively ameliorate even the carcinogenic effects of aflatoxin.

**Keywords:** Aflatoxin, triphala, liver

Amelioration of aflatoxin toxicity by dietary herbal treatment is a recent concept. Triphala (containing composite mixture of *Emblica officinalis*, *Terminalia chebula* and *T. bellirica*) is known to have hepatoprotective property (Tasduq *et al.*, 2005). With this fact in mind triphala was utilized to counteract the toxic effects of aflatoxin in this study.

## Materials and Methods

*Aspergillus parasiticus* var. *globosus* 411 culture maintained on potato dextrose agar at the AICRP on Poultry, Veterinary College, Mannuthy was used in this study. Aflatoxin was produced in rice as per the method of Shotwell *et al.* (1966). The representative sample of fungal culture material were quantified by thin layer chromatography (AOAC., 1990) at Animal Feed Analytical and Quality Control Laboratory, TANUVAS, Namakkal. The rice culture yielded 27 ppm of aflatoxin which was

incorporated into the ration to give a final concentration of 0.5 ppm of aflatoxin.

The study was conducted for a period of two months with twenty four rabbits aged four weeks. Rabbits were weighed individually and divided into three treatment groups namely group I, group II and group III with eight rabbits each. Aflatoxin contaminated diet at 0.5 ppm and combination of aflatoxin added feed (0.5 ppm) and triphala at four percent were given for group I and group II respectively. Group III was provided with control diet. Standard management practices were followed throughout the experimental period. Feed and water were provided *ad libitum*. Different parameters like serum profile, gross and histopathological changes were studied.

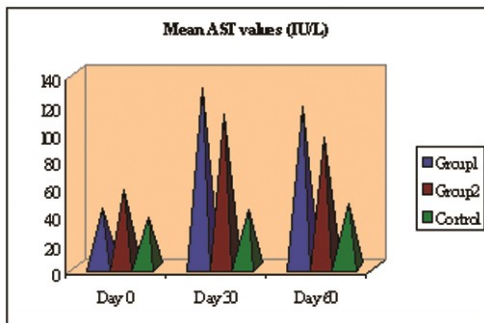
## Results and Discussion

Serum enzyme analysis revealed a significant ( $P < 0.05$ ) increase in the Aspartate amino transferase (AST), Alanine amino transferase (ALT) and Alkaline Phosphatase (ALP) values in the aflatoxin fed group and triphala group, but triphala group showed numerically lower values. Increase in serum enzymes observed on 30<sup>th</sup> and 60<sup>th</sup> day indicated hepatic damage. (Fig.s 1, 2 & 3). The increased levels of serum enzymes in aflatoxicosis were reported by many workers (Arulmozhi *et al.*, 2000; Rohilla *et al.*, 2001). Bhanuprakash *et al.* (2006) proved treatment with Partysmart<sup>®</sup>, a herbal formulation containing *Emblica officinalis* could effectively reduce the levels of serum AST, ALP, ALT in alcoholic liver diseases.

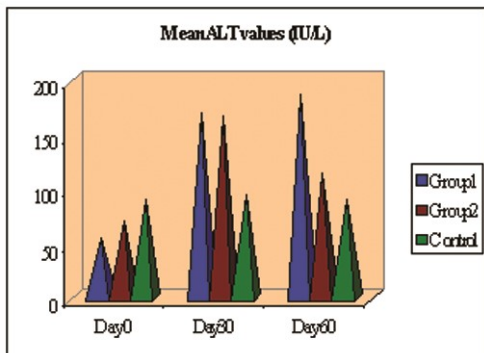
\* Part of M. V. Sc. thesis submitted by the first author to the Kerala Agricultural University, Thrissur

1. Vocational Teacher, G.V.H.S.S Thamarassery

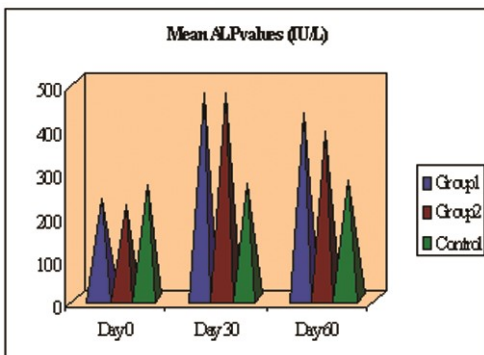
2. Professor and Head



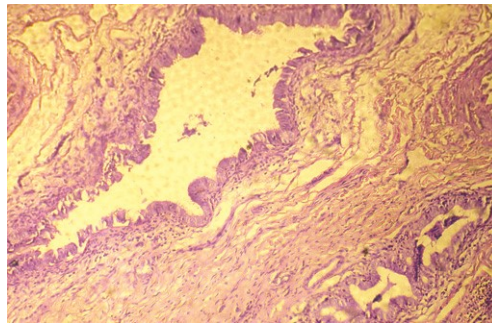
**Fig. 1** Means values of Aspartate aminotransferase (AST) (IU/L)



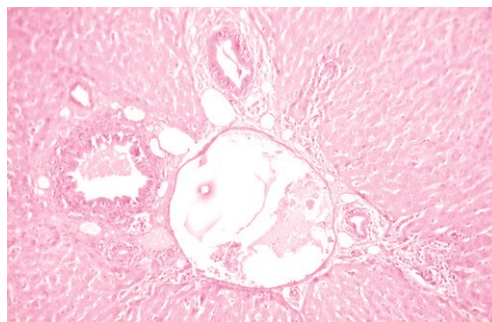
**Fig. 2** Mean values of Alanine aminotransferase (ALT) (IU/L)



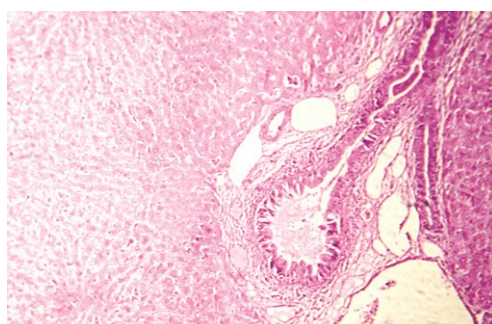
**Fig. 3** Mean values of Alkaline phosphatase (ALP) (IU/L)



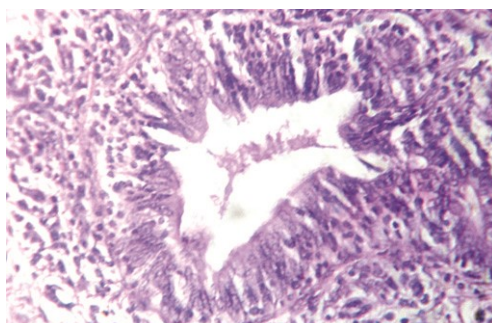
**Fig. 5.** Liver – dense abundant supporting stroma in cholangiocellular carcinoma (H&EX100)



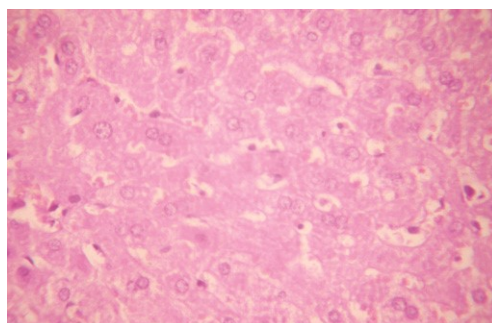
**Fig. 6.** Liver – bile duct proliferation in triphala group (H&EX100)



**Fig. 7.** Liver – well maintained hepatic architecture in triphala group (H&EX100)



**Fig.4.** Liver – neoplastic cells almost filling the lumen of bile duct in cholangiocellular carcinoma (H&EX400)



**Fig. 8.** Liver – binucleate actively dividing hepatocytes and kupffer cell proliferation in triphala supplemented group (H&EX400)

The rabbits that died during the course of the experiment and the animals euthanised at the end of two months were subjected to detailed postmortem examination. The gross changes observed in the liver of rabbits fed with 0.5 ppm aflatoxin contaminated feed were pale to yellowish discolouration and enlargement with distended gall bladder consisting of thick greenish bile. The liver was hard in consistency and nodular lesions of varying sizes were observed in three rabbits. The enlargement of liver indicated aflatoxin induced degenerative damage.

Tissues of aflatoxin fed rabbits at 0.5 ppm level (group I) revealed histological alterations characteristic of aflatoxicosis. The vascular changes observed were central venous congestion, dilatation and congestion of sinusoids and portal vessels. Aflatoxin produced extensive degenerative changes in the hepatic tissue. Diffuse fatty degeneration characterized by vacuolation of the cytoplasm of hepatocytes pushing the nucleus to one side was observed. Injury to hepatocytes can lead to accumulation of lipids because of decreased formation or export of lipoprotein by hepatocytes and decreased oxidation of fatty acids within hepatocytes. Here aflatoxin damaged the hepatic cells and led to fatty change (Mc Gavin *et al.*, 2007).

Chronic hepatic lesions were evident by biliary hyperplasia, mononuclear infiltration and fibrous tissue proliferation. Megalocytosis with enlarged nucleus were seen. The hyperplastic bile duct epithelium formed finger like projections into the lumen. There was excessive infiltration of mononuclear cells in the hepatic and kidney parenchyma. Mononuclear infiltration could be related to immunological response by the body to get rid of the toxic materials and chronic lesions are considered to be hepatic response to aflatoxin induced injury. (Mc Gavin *et al.*, 2001).

The nodular lesions seen in the liver of three rabbits on histopathological examination revealed cholangiocellular carcinoma. There was numerous glandular structures lined by cuboidal or columnar cells resembling those of biliary epithelium and dense abundant stroma (Fig.s 4 and 5). Formation of cholangiocellular carcinoma in aflatoxicosis was observed by Maryamma *et al.* (1994) in pigs.

The gross and microscopical lesions in rabbits fed with triphala at four per cent level in aflatoxin added feed were similar to those observed in toxin fed but in reduced magnitude and severity. There was no firmness of liver and nodular lesions in triphala group. In the liver of triphala treated group there were congestion of central veins and sinusoidal spaces. Diffuse fatty change and wide spread necrosis with focal mononuclear accumulation were also observed but in less severity compared to the toxin fed group. Proliferation of bile ducts (Fig. 6) with mild periductular accumulation of mononuclear cells was seen in a few cases. Fibrous tissue proliferation was scanty and architecture of the liver was well maintained (Fig. 7). Binucleate actively dividing hepatocytes and Kupffer cell reaction were abundant in the parenchyma of triphala supplemented group (Fig. 8). The liver of control group animals appeared morphologically and histologically normal throughout the experimental study.

Results of the present study revealed that aflatoxin at 0.5 ppm level in the feed adversely affected serum enzymes besides producing gross and histopathological alterations in the liver. But inclusion of triphala at four per cent level in the diet significantly ameliorated the toxicity by hepatoprotective and anti carcinogenic effects. Constituents of triphala has been reported to be a rich source of vitamin C, ellagic acid, gallic acid, chebulinic acid, bellericanin,  $\beta$ -sitosterol, flavanoids and polyphenols (Girdhani *et al.*, 2005). It harbours constituents with promising antimutagenic and anticarcinogenic potential that should be investigated in detail.

## References

- AOAC. 1990. *Official Methods of Analysis* 15<sup>th</sup> ed. Association of Official Analytical Chemists., Washington, D.C.
- Arulmozhi, A., Varghese, K., Ismail, P.K. and Peethambaran, P.A. 2000. Haematobiochemical changes in experimental aflatoxicosis in broiler chicken. *Indian J. Vet. Pathol.*, **24**:143-144.
- Bhanuprakash, M.L., Sathyanarayana, S.K., Vijayarathi, S.K. and Upendra, H.A. 2006. Serum biochemistry, organ weights and performance of broiler chickens fed aflatoxin, ochratoxin and

- toxin binder. *Indian Vet. J.*, **83**:159 - 161.
- Girdhani, S., Bhosle, S.M., Thulsidas, S.A., Kumar, A. and Mishra, K.P. 2005. Radiosensitizing agents in cancer chemo-radiotherapy. *J. Can. Res. Ther.*, **1**:129-131
- Maryamma, K.I., Rajan, A., Gopalakrishnan, N.M. and Manomohan, C.B. 1994. Effect of dietary protein levels on aflatoxin induced hepatocarcinogenesis in pigs. *J. Vet. Anim. Sci.*, **25**:19-24.
- Mc Gavin, M.D., Carlton, W.W., Zachary, J.F. 2001. *Thomson's Special Veterinary Pathology* .3<sup>rd</sup> ed. Mosby., Missouri, 755p.
- Mc Gavin, M.D., Zachary, J.F. 2007. *Pathologic Basis of Veterinary Disease*. 4<sup>th</sup> ed. Mosby., Missouri, 1476p.
- Rohilla, P.P., Singh, G. and Bujarbaruah, K.M. 2001. Therapeutic efficacy of livfit vet against aflatoxicosis in rabbits. *Indian Vet. Med. J.*, **25**:91-94.
- Shotwell, O.L., Hesseltine, C.W., Stubblefield, R.D. and Sorenson, G.W. 1966. Production of aflatoxin on rice. *Appl. Microbiol.*, **14**:425-428.
- Tasduq, S., Mondhe, D.M., Gupta, D., Baleshwar, M and Johri, R.K. 2005. Reversal of fibrogenic events in liver by *Embllica officinalis* (fruit), an Indian natural drug. *Biol. Pharm. Bull.*, **28** : 1304.

