



Histomorphological studies on the testicular capsule of crossbred Large White Yorkshire boars (*Sus scrofa domestica*)

K. P. Abhin Raj^{1*}, A. R. Sreeranjini², S. Maya³, V. N. Vasudevan⁴ and N. S. Sunilkumar⁵

Department of Veterinary Anatomy and Histology,
College of Veterinary and Animal Sciences, Mannuthy, Thrissur, Kerala 680651
Kerala Veterinary and Animal Sciences University, Kerala, India

Citation: Abhin Raj, K. P., Sreeranjini, A. R., Maya, S., Vasudevan, V. N. and Sunilkumar, N.S. 2022. Histomorphological studies on the testicular capsule of crossbred Large White Yorkshire boars (*Sus scrofa domestica*). *J. Vet. Anim. Sci.* **53**(2): 154-157

DOI: <https://doi.org/10.51966/jvas.2022.53.2.154-157>

Received: 08.03.2021

Accepted: 30.03.2021

Published: 30.06.2022

Abstract

The present study was conducted on the testes of six healthy adult Large White Yorkshire pigs. Parenchyma of testes of adult boars was surrounded by a thick fibrous testicular capsule composed of inner tunica vasculosa, middle tunica albuginea, and outer visceral layer of tunica vaginalis. Tunica vasculosa was prominent and characterised by loose connective tissue contained numerous blood vessels. Tunica albuginea was composed of irregular connective tissues made up of collagen, elastin and reticular fibres. Visceral layer of tunica vaginalis was found as outer thin layer of testicular capsule comprised of mesothelium and connective tissue layer. Connective tissue layer was blended with underlying connective tissues of tunica albuginea.

Keywords: Histomorphology, pig, testicular capsule

According to Leena *et al.* (2004), only a few states in India are successful in modern pig farming, with Kerala being the most notable. Availability of plenty of swill and food habits, makes pig farming a beneficial livestock sector in Kerala (Kannan *et al.*, 2008). Testes are the primary reproductive and endocrine organs or gonads in the male, responsible for the production of functional spermatozoa, secretion of hormones and factors that involve all aspects of sexual development and reproductive functions. Studies and literature pertaining to histomorphology of testes of pigs are scanty, hence the study was undertaken.

[#]Part of the MVSc thesis of the first author submitted to the Kerala Veterinary and Animal Sciences University, Pookode, Wayanad, Kerala

1. MVSc Scholar
2. Associate professor
3. Professor and Head
4. Assistant Professor, Department of Livestock Products Technology
5. Assistant Professor

*Corresponding author: email: abhinrajtsy@gmail.com Ph: 8086410811

Copyright: © 2022 Abhin Raj *et al.* This is an open access article distributed under the terms of the Creative Commons Attribution 4.0 International License (<http://creativecommons.org/licenses/by/4.0/>), which permits unrestricted use, distribution, and reproduction in any medium, provided the original author and source are credited.

Materials and methods

The present study was conducted on the testes of six healthy adult Large White Yorkshire (LWY) pigs slaughtered at the Meat Technology Unit, Kerala Veterinary and Animal Sciences University. Tissue samples of testes were collected from cranial, middle and caudal parts of the testes and fixed in 10% neutral buffered formalin for 48 hours. Paraffin blocks were made by alcohol-xylene sequence (Luna, 1968). The sections were cut at 5 μ thickness and stained by Haematoxylin and eosin (H&E) staining for general cytoarchitectural studies (Luna, 1968). Special staining methods like Van Gieson's staining for collagen fibres (Luna, 1968), Masson's trichrome staining for muscles and collagen fibres (Luna, 1968), Verhoeff's staining (Singh and Sulochana, 1996) for elastic fibres, Gomori's method for reticular fibres (Luna, 1968) and Phosphotungstic acid haematoxylin (PTAH) staining for muscles (Luna, 1968) were also employed.

Results and discussion

Testicles of crossbred Large White Yorkshire boars were found white in colour, large, regularly elliptical shaped, placed at the perineal region and directed backwards and upwards forming a prominent landmark about 6-8 cm below the anus. Parenchyma of the testes of adult boars was surrounded by a thick fibrous testicular capsule and was characterised by regularly arranged dense connective tissue, made up of three layers viz., inner tunica vasculosa, middle tunica albuginea and outer visceral layer of tunica vaginalis (Fig. 1). These findings were similar to the reports of Ahmed and Sinowatz (2005) in bull, Dhyana *et al.* (2016), Singh *et al.* (2019) and Singh *et al.* (2020) in adult boar and Khan *et al.* (2019) in buck.

The innermost, highly vascularised and prominent tunica vasculosa, which was contained in the deeper portion of the capsule was distinguished by dense regular connective tissue (Fig. 1). These observations are in accordance with the reports of Shukla *et al.* (2013) in stallion and Dhyana *et al.* (2016), Singh *et al.* (2019), Singh *et al.* (2020) in adult boar. Tunica albuginea, the middle layer of

testicular capsule had dense regular connective tissue which was composed of collagen (Fig. 2), elastic (Fig. 2) and reticular fibres (Fig. 3) along with fibroblasts, smooth muscle fibres (Fig. 4) and a few blood vessels. These observations are similar to the reports given by Shukla *et al.* (2013) in stallion, Dhyana *et al.* (2016) in domestic pig of Hyderabad, Singh *et al.* (2019) in local pig (Zovawk) of Mizoram and Singh *et al.* (2020) in LWY boar and contrary to the findings of Trautmann and Fiebiger (1952), who discovered tunica vasculosa in the centre of the testicular capsule in both stallion and boar.

The inner layer of capsule continued as inconspicuous connective tissue trabeculae and divided the parenchyma of the testis into several inconspicuous lobules (Fig. 5). Trabeculae were observed as thick strands of collagen and elastic fibres, supplied with blood and lymph vessels. These observations are in accordance with the previous reports of Al-Kelaby *et al.* (2017) in ram and buck and Dhyana *et al.* (2016) and Singh *et al.* (2020) in boar but are not in agreement to the observations of Ahmed and Sinowatz (2005) in bull and Shukla *et al.* (2013) in stallion, who found that the connective tissue structure was not as distinct and thus lobulation was insignificant.

Visceral layer of tunica vaginalis was found as a thin outer layer of testicular capsule comprised of outermost mesothelium and underlying connective tissue layer (Fig. 1). Connective tissue layer was formed of collagen fibres and a few elastic and reticular fibres that blended with underlying connective tissues of tunica albuginea as observed as Dhyana *et al.* (2016) in pigs. Due to this blending, visceral layer of tunica vaginalis could not be clearly delineated from the outer fibrous layer of testicular capsule

Conclusion

The results presented on the histology of testicular capsule of boars are those of normal, adult, sexually active ones. Parenchyma of the testes of adult boars was surrounded by a thick fibrous testicular capsule and was characterised by regularly arranged dense connective made up of three layers viz., inner tunica vasculosa, middle tunica albuginea and outer visceral

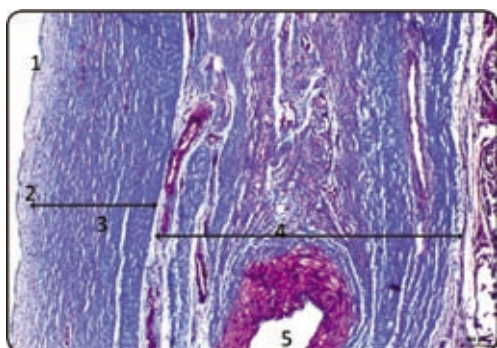


Fig. 1. Cross section of testicular capsule with visceral layer of tunica vaginalis. Masson's trichrome method x 100

1. Mesothelium,
2. Visceral layer of tunica vaginalis,
3. Tunica albuginea,
4. Tunica vasculosa, 5. Artery

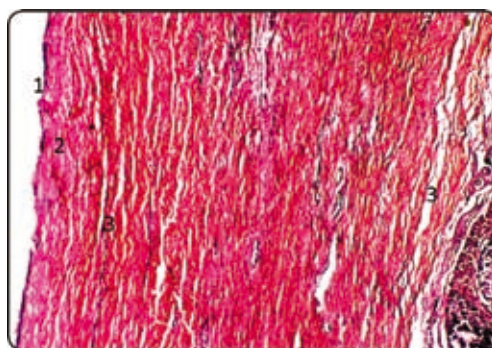


Fig. 2. Cross section of testicular capsule with visceral layer of tunica vaginalis. Verhoeff's elastic stain x 100

1. Mesothelium, 2. Collagen fibres,
3. Elastic fibres

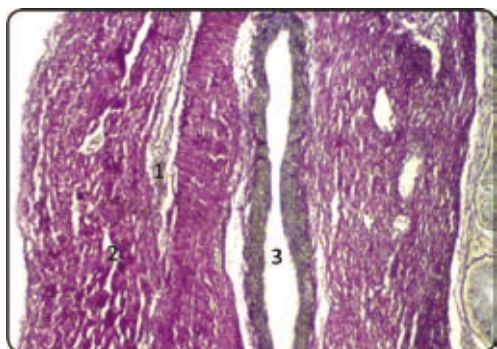


Fig. 3. Cross section of testicular capsule with visceral layer of tunica vaginalis. Gomori's method for reticular fibres x 100

1. Reticular fibres, 2. Collagen fibres,
3. Artery

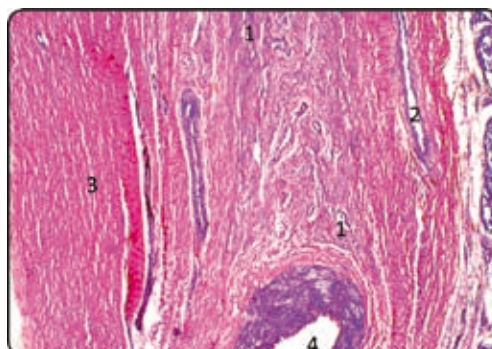


Fig. 4. Cross section of testicular capsule with visceral layer of tunica vaginalis. PTAH method for muscles x 100

1. Smooth muscle, 2. Vein, 3. Collagen fibres,
4. Artery

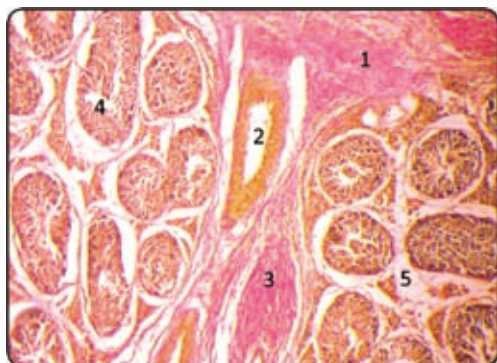


Fig. 5. Cross section of testis showing origin of trabecula from testicular capsule. van Gieson's method x 200

1. Tunica vasculosa, 2. Artery, 3. Trabecula,
4. Seminiferous tubule, 5. Testicular lobule

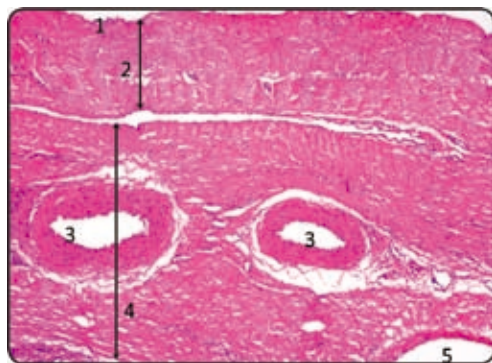


Fig. 6. Cross section of testicular capsule with visceral layer of tunica vaginalis. H&E x 100.

1. Mesothelium, 2. Fibrous layer, 3. Artery,
4. Vascular layer, 5. Vein

layer of tunica vaginalis. Tunica albuginea was the middle layer of testicular capsule which was composed of collagen, elastic and reticular fibres along with fibroblasts, smooth muscle fibres and a few blood vessels. The presence of smooth muscle cells in the capsule could be attributed to the transport of spermatozoa whereas the collagen fibres and fibroblasts for the mechanical support.

Acknowledgement

The authors are thankful to the Kerala Veterinary and Animal Sciences University for providing the facilities needed for carrying out the research.

Conflict of interest

The authors declare that they have no conflict of interest.

References

- Ahmed, A.E. and Sinowatz, F. 2005. Morphological, glycohistochemical and immunohistochemical studies on the embryonic and adult bovine testis. *Ph.D. Thesis*, Ludwig Maximilians University, Munchen, 234p.
- Al-Kelaby, W.J.A., Al-Mahmodi, A.M.M. and Al-Ramahy, A.A.J. 2017. Microscopic and biometric investigations of the testes in adult ram and adult buck in Al-Najaf Al-Ashraf Province. *Al-Qadisiya J. Vet. Med. Sci.* **16**: 105-110.
- Dhyana, V.R., Rajendranath, N., Pramod Kumar, D. and Raghavender, K.B.P. 2016. Microanatomical studies on the testis of domestic pig (*Sus scrofa domestica*). *Int. J. Sci. Environ. Tech.* **5**: 2226-2231.
- Kannan, A., Francis Xavier, Raja, T.V. and Murugan, M. 2008. Awareness and needs of pig farmers in Kerala. *J. Vet. Anim. Sci.* **39**: 36-39.
- Khan, S.A., Kalhor, I.B., Gandahi, J.A., Vistro, W.A., Kalwer, Q., Ali, I., Khokhar, T.A. and Mangi, M.H. 2019. Puberty associated micro anatomical modification in testes and epididymis of Teddy goat (*Capra hircus*). *Pure Appl. Biol.* **8**: 1281-1286.
- Leena, A., Anil, S.S. and Mercey, K.A. 2004. Prediction of weight of pigs using body measurements. *J. Vet. Anim. Sci.* **35**: 61-65.
- Luna, L. G. 1968. *Manual of Histologic Staining Methods of the Armed Forces Institute of Pathology*. (3rd Ed.). Mc Graw Hill Co., New York, 258p.
- Shukla, P., Bhardwaj, R.L. and Rajput, R. 2013. Histomorphology and micrometry of testis of chamurthi horse. *Ind. J. Vet. Anat.* **25**: 36-38.
- Singh, T.S., Kalita, P.C., Choudhary, O.P., Kalita, A. and Doley, P.J. 2019. Histomorphological studies on the testis of local pig (Zovawk) of Mizoram. *Indian. J. Anim. Res.* **53**: 1455-1458.
- Singh, T.S., Kalita, P.C., Choudhary, O.P., Kalita, A. and Doley, P.J. 2020. Histological, micrometrical and histochemical studies on the testes of Large White Yorkshire Pig (*Sus scrofa domestica*). *Indian J. Anim. Res.* **1**: 1-4.
- Singh, U. B. and Sulochana, S. 1996. *Handbook of Histological and Histochemical Techniques*. Premier publishing House, Hyderabad, 111p.
- Trautmann, A and Fiebiger, J. 1952. *Fundamentals of the histology of domestic animals*. United States of America by George banta publishing company, Menasha, Winconsin, 269p.