



PROSTATIC ABSCESS IN A GERMAN SHEPHERD DOG – A CASE REPORT*

Received - 08.10.10

Accepted - 05.04.11

Prostatic abscesses develop either after fusion of small areas of infection within the gland or after infection of prostatic cysts (Baker and Lumsden, 1999). They can also develop as a result of bacterial contamination spreading from another part of the urinary tract, by haematogenous route, from cysts that become secondarily infected or as a sequel to chronic prostatitis where cavities of purulent fluid were found within the parenchyma of the prostate.

A six year old intact male German shepherd dog weighing 25 kg was presented to Veterinary College Hospital, with a history of anorexia, vomiting, melena and dyschezia for 10 days. Significant changes were recorded on detailed clinical examination of the dog. The animal was found dehydrated with difficulty to stand up. The respiration was shallow and uraemic smell was present from mouth. The temperature was 102°F; pulse 120/min, respiration 17/ min and the visible mucous membranes were congested.

On digital rectal palpation, the prostate gland was found to be isothermic. Position of the prostate gland was partly in the pelvic and abdominal cavities. Prostate was found to be moderately smooth and soft in consistency. The prostate gland was enlarged asymmetrically and movable upon rectal examination. The animal exhibited slight pain during rectal examination.

On ultrasonography, multiple hypoechoic cavitory lesions with irregular borders were visualised in the prostate gland. The fluid within the lesion had mixed echogenicity/ flocculent appearance (Fig.1). The prostatic length, depth, width and volume were 5.79, 6.28, 5.02 and 95.46 cm³ respectively. Both the kidneys were enlarged with thickened cortex and the corticomedullary distinction was absent. Urinary bladder with

thickened wall containing mixed echogenic substances (Fig.2) was observed. Splenomegaly was also present.

Prostatic fluid collected by prostatic massage combined with urethral catheterisation, was purulent and cytological examination revealed large number of degenerated neutrophils and bacteria. Culture and sensitivity test of prostatic fluid revealed the presence of *Escherichia coli*, which was sensitive to tetracycline, enrofloxacin and chloramphenicol.

Clinical pathology revealed leucocytosis (25,500/cu.mm) with neutrophilia (88%) and lymphopenia (12%). Mild anaemia was also reported in haematology. Hyperglobulinaemia (5.4 g/dl), hypoglycaemia (57 mg/dl) and azotaemia (serum creatinine - 28 mg/dl and BUN - 675 mg/dl) were observed in the present study. Serum total acid phosphatase (8.5 U/L) and prostatic fractions (3.6 U/L) were elevated. The serum testosterone was within the normal range.

Escherichia coli was isolated from both prostatic fluid and urine. Antibiotics such as tetracycline, enrofloxacin and chloramphenicol were sensitive to both samples whereas, amoxicillin was sensitive in the case of urine sample only.

The urine sample was acidic in nature and had the specific gravity of 1.008. Blood pigment was absent while proteinuria was (3+). The cultural examination of urine sample isolated *E.coli* organism, which was sensitive to tetracycline, enrofloxacin, amoxicillin and chloramphenicol.

The treatment was started with enrofloxacin @ 10 mg/kg b.wt. along with IV fluids, antiemetics (Inj. Metoclopramide @ 0.2 mg/kg b. wt SC) and proton pump inhibitors (Inj. Pantoprazole @ 1 mg/kg BW IV). But the animal died on the second day of presentation.

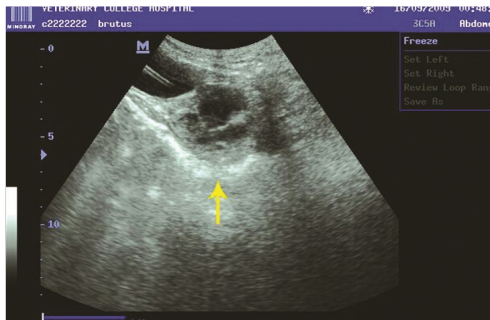

Fig. 1. Fluid with flocculent appearance

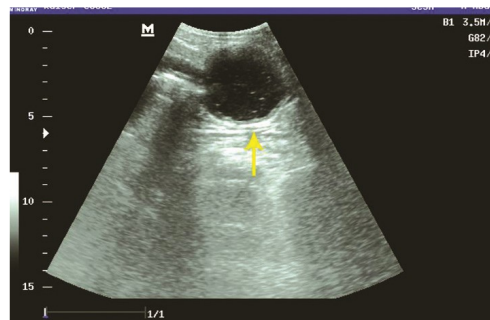


Fig. 2. Urinary bladder with thickened wall containing mixed echogenic materials

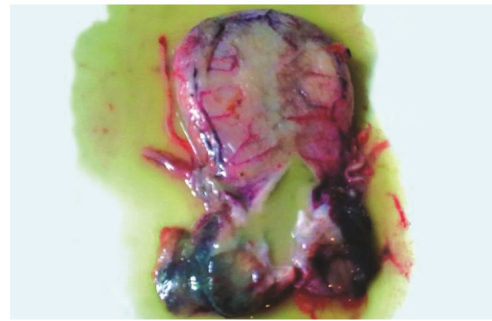


Fig.3. Enlarged Prostate filled with pus

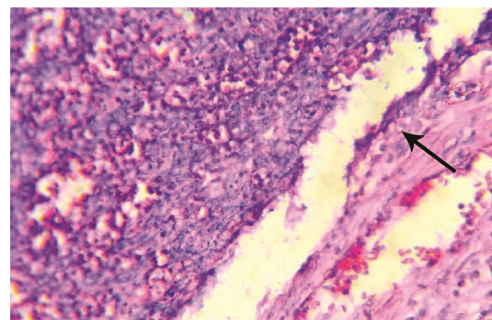


Fig.4. Distended acini with hyperplastic glands

Postmortem examination revealed gastroenteritis, irregular kidneys with inflammatory changes and necrotic areas and splenomegaly with nodular changes. Both the lobes of prostate were enlarged and filled with pus (Fig. 3). The right lobe was bluish to black in colour. The urinary bladder was also filled with purulent fluid and echymotic patches were present in bladder mucosa.

Histopathology of prostate gland revealed an abscess wall that was formed by inflammatory granulation tissue. Some acini were distended with necrotic material inside. Stroma showed dense infiltration by lymphocytes, plasma cells and polymorphs. Some areas had hyperplastic glands (Fig. 4).

A clinical diagnosis of prostatic abscess was made on the basis of above findings. Lowseth *et al.* (1990) reported clinical signs of prostatic abscess as anorexia, fever, depression, gait abnormalities, tenesmus, dysuria and caudal abdominal pain. Clinical signs often vary depending on the size of the abscess and whether the infection became systemic or not (Smith, 2008). Uraemic smell from mouth observed in this case might be due to concurrent renal failure, which is ascertained by increased serum creatinine, ultrasonographic and autopsy findings.

In the present case, the prostate was

asymmetrically enlarged, movable, soft and painful on palpation. Boland *et al.* (2003) reported that the rectal examination of dog with prostatic abscess revealed asymmetrical enlargement of prostate and pain on palpation. Palpable fluctuant areas were present in prostatic abscess as reported by Davidson (2003).

Cytopathological studies of prostatic fluid revealed large number of degenerated neutrophils and bacteria. The culture of prostatic fluid revealed presence of *E. coli*. Similar findings were reported by Boland *et al.* (2003).

Leucocytosis (25500/cu.mm) with neutrophilia (88%) and lymphopenia (12%) was observed in this case whereas Boland *et al.* (2003) reported that haematology and serum biochemical result were variable in prostatic abscess and the most common abnormalities included mild to moderate leucocytosis, lymphopenia or both. Mild anemia was also reported in haematology. Hyperglobulinaemia, hypoglycaemia and azotaemia were observed in the present study. Davidson (2003) also reported similar findings.

Serum and prostatic fraction total acid phosphatase were elevated. The reason for this might be due to degenerative process of the prostatic tissue by the abscess formed as

opined by Corazza *et al.* (1994) who reported that prostatic acid phosphatase was liberated during degeneration which was induced by dihydrotestosterone. The serum testosterone was within the normal range.

The effectiveness of the treatment could not be evaluated as the animal died on the second day of treatment due to severe septicaemia.

Histopathological examination of prostate gland revealed abscess wall formed by inflammatory granulation tissue, acini with necrotic material, lymphocytes, plasma cells and polymorphs infiltration into the stroma that were all could be correlated with ultrasonographic findings and prostatic fluid cytology.

Summary

A case of prostatic abscess was diagnosed in a German shepherd dog. Transrectal digital palpation, ultrasonography and clinicobiochemical parameters were studied in detail. The changes in ultrasonography correlated to histopathological findings confirming the diagnosis.

References

- Baker, R. H., Lumsden, J. H. 1999. Reproductive tract. In: Baker, R. H. and Lumsden, J. H.(Eds.) *Color Atlas of Cytology of the Dog and Cat* (CV Mosby, St. Louis. pp. 235–251.
- Boland, L. E., Hardie, R. J., Gregory, S. P. and Lamb, C. R. 2003. Ultrasound guided percutaneous drainage as the primary treatment for prostatic abscesses and cysts in dogs. *J. Am. Anim. Hosp. Assoc.*, **39**:151-159.
- Corazza, M., Guidi, G., Romagnoli, S., Tognetti, R. and Buonaccorsi, A. 1994. Serum total prostatic and non prostatic acid phosphatase in healthy dogs and in dogs with prostatic diseases. *J. Small. Anim. Prac.*, **35**: 307-310.
- Davidson, J. R. 2003. Prostatic diseases of the dog. *Waltham Focus*, **13**:4-10.
- Lowseth, L. A., Gerlach, R. F., Gillet, N. A. and Muggenburg, B. A. 1990. Age-related changes in the prostate and testes of the beagle dog. *Vet. Pathol.*, **27**:347-353.
- Smith, J. 2008. Canine prostatic disease: A review of anatomy, pathology, diagnosis and treatment. *Theriogenology*, **70**:375-383.
- Sindhu K. Rajan¹, Usha Narayana Pillai², P. C. Alex³, K. M. Jayakumar⁴ and Metilda Joseph⁵**
Department of Clinical Veterinary Medicine
College of Veterinary and Animal Sciences
Mannuthy 680 651, Thrissur.

* Part of M.V.Sc. thesis submitted by the first author to the Kerala Agricultural University

¹ Veterinary Surgeon, AHD, Kerala

² Associate Professor

³ Director of Clinics, KVASU

⁴ Professor and Head, University Veterinary Hospital, Kakkalai

⁵ Associate Professor, Dept. of Gynaecology, Obstetrics and Animal Reproduction