



Studies on infectious etiologies associated with neurological disorders in pigeons in Kerala

Rani Maria Thomas¹, P.M Deepa^{2*} and Prejit³

Department of Veterinary Epidemiology and Preventive Medicine,
College of Veterinary & Animal Sciences, Pookode - 673576
Kerala Veterinary and Animal Sciences University
Kerala, India.

Citation: Thomas, R.M., Deepa, P.M and Prejit. 2022. Studies on infectious etiologies associated with neurological disorders in pigeons in Kerala. *J. Vet. Anim. Sci.* 53(4):

DOI: <https://doi.org/10.51966/jvas.2022.53.4>.

Received: 28.01.2022

Accepted: 15.09.2022

Published: 31.12.2022

Abstract

Pigeons are reared as a symbol of peace, love, gentleness and spirit messengers and now-a-days also for meat, as ornamental pet bird or as an experimental animal. There are about 400 varieties of fancy pigeons and little is known about the diseases and management of these birds. Heavy mortality has been observed in the pigeons that shows neurological manifestations. The present study is aimed at diagnosis of infectious diseases causing neurological signs in pigeons. The study was conducted in the different pigeon lofts of four districts in Kerala and a total of 44 pigeons comprising 21 fancy breeds were included. These birds were screened for major infectious etiologies causing neurological signs like paramyxoviral infection, salmonellosis and Haemoproteus infection. The birds were also screened for presence of ectoparasites by visual examination. The study showed 63.63 per cent positive for paramyxoviral infection using antigen NDV kits. The occurrence of Haemoproteus infection was 54.7 per cent in Giemsa-stained blood smears and 63.63 per cent in PCR amplifying *cyt b* gene. *Pseudolynchia canariensis* could be detected in pigeons. Isolation and identification of *Salmonella* from faecal samples were done by culture and biochemical tests and found to be 22.2 per cent. Combined infections of paramyxovirus infection with Haemoproteus, paramyxovirus infection with *Salmonella*, Haemoproteus with *Salmonella* and infection of all the three etiologies were the interesting finding of the study. The present study is one of its kind in Kerala and also in India. The study warrants the prevention and control of these infectious diseases which has great zoonotic potential.

Keywords: Pigeon, Paramyxovirus, *Salmonella*, Haemoproteus

Pigeons were among the most ancient domesticated birds in the world. Paul *et al.* (2015) reported that the most common infectious diseases in pigeon at Bangladesh were salmonellosis

1. MVSc Scholar
2. Associate Professor
3. Assistant Professor, Dept of Veterinary Public Health

*Corresponding author: deepapm@kvasu.ac.in, Ph: 9496400982

Copyright: © 2022 Rani *et al.* This is an open access article distributed under the terms of the Creative Commons Attribution 4.0 International License (<http://creativecommons.org/licenses/by/4.0/>), which permits unrestricted use, distribution, and reproduction in any medium, provided the original author and source are credited.

(20.3 per cent), pigeon pox (18.9 per cent), New castle disease (6.5 per cent), pigeon malaria (3.1 per cent), coccidiosis (3.5 per cent) and colibacillosis (4.9 per cent). Neurological disease in pigeons is often caused by both infectious, non-infectious and nutritional etiologies. The infectious etiologies of nervous signs include Newcastle disease by avian paramyxovirus serotype 1, avian encephalomyelitis, septicaemic form of avian listeriosis (Ali *et al.*, 2014) salmonellosis, (Hooimeijer and Dorrestein, 1997) and *Haemoproteus* infection (Joshi *et al.*, 2017).

Even though helminth and *Haemoproteus* infections have been reported in pigeons, no systematic studies have been conducted regarding the etiologies of neurological syndromes affecting these birds, which are responsible for high rate of mortality among pigeons. Hence the present study was conducted to understand the incidence of the diseases associated with neurological signs in pigeons from different districts of Kerala and to identify the major infectious pathogens causing neurological signs in fancy pigeons.

The study was conducted in different pigeon lofts in Wayanad, Kozhikode, Thrissur and Alappuzha districts of Kerala. Samples collected from all the pigeons include cloacal swab, EDTA blood, blood smear and ectoparasites. The thin blood smears were fixed using methanol, stained using Giemsa stain and examined under oil immersion. The blood samples were stored at -20°C till further use. DNA was isolated from blood using DNeasy Blood and Tissue kit (QIAGEN) following manufacturers instruction. Primers used for the amplification of mitochondrial *cytb* gene coding for *Haemoproteus* organism were F:5'-TTAGATACATGCATGCAA CTG GTG-3' and R:5'-TAGTAATAACAGTTG CAC CCC AG-3'. The PCR reaction was performed in 25 µL, with 1µM of each primers, 12.5µL of PCR master mix (Emerald Amp GT PCR Master mix), 8.5µL of nuclease free water and 2µL of genomic DNA. The DNA amplification was done under the following conditions: 94°C for 5 minutes, 40 cycles at 94°C for 60 seconds, 60°C for 60 seconds and 72°C for 60 seconds, with a final extension at 72°C for 60 seconds. Samples

that showed a 207 bp band were considered positive. Ectoparasites were identified based on morphological characteristics (Kheirabadi *et al.*, 2016). Cloacal swabs collected using sterile swabs from pigeons showing neurological signs were tested by lateral flow assay using rapid antigen NDV kits (Bionote, Korea) and bands at test and controls were considered as positive. Faecal samples from affected birds were collected for laboratory examination in sterile cotton swab in a screw capped tube. The faecal swabs were inoculated in selenite F broth and incubated for 24 hr at 37°C. The broth was streaked on BHIA and MacConkey agar and incubated for 24 hr at 37°C and non-lactose fermenting colonies were selected and streaked in Petri plates containing Salmonella Shigella agar and incubated for 24hr at 37°C. The isolates were identified based on morphology, cultural characteristics and biochemical tests as per Barrow and Feltham (1993) and Quinn *et al.* (2004). Primarily the isolates were stained using Gram's staining, catalase and oxidase test. Biochemical tests *viz.* indole production, methyl red test, Voges-Proskauer test, Citrate utilisation test, Urease activity and Triple sugar iron agar test were done to characterize the *Salmonella* organism. The *in vitro* antibiotic sensitivity of the isolates was studied as per CLSI guidelines (2016) using disc diffusion technique (Bauer *et al.*, 1966). The blood smears stained with Giemsa showed halter shaped gamonts of *Haemoproteus columbae* in nucleated erythrocytes in affected birds (Fig. 1). Ectoparasites were collected from head, under parts of wings, feathers *etc.* and preserved in 70 per cent alcohol and identified as *Pseudolynchia* sp. based on morphological characteristics. Out of 44 pigeons examined,

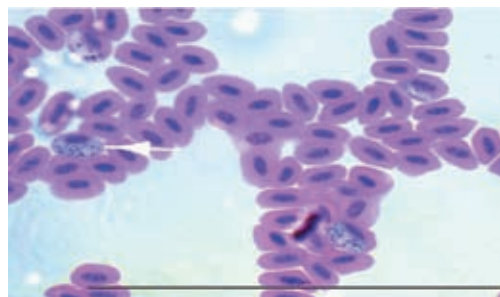


Fig.1. Gamonts of *Haemoproteus* in RBC (Giemsa stained blood smears, 100x)




Fig.2. Identification of *Haemoproteus columbae* by detection of *cytb* gene by PCR
M: DNA ladder L1: Positive control. L2, L3, L4, L5: Samples. L6: Negative control

52.2 per cent (23 out of 44) were positive for *Haemoproteus* infection. *Haemoproteus columbae* was confirmed in 28 samples (63.63 per cent) by PCR targeting *cyt b* gene by observing 207 bp sized amplicon in agarose gels (Fig.2).

Similar finding (58.3 per cent) was reported by Shinde *et al.* (2008) from urban localities of Mumbai, India. The primary target of the haemosporidian parasite could be lungs, liver, spleen and brain. Damage to the capillaries in the brain can result in neurological signs including mentation changes, problem with balance and blindness (La Pointe *et al.*, 2005).

Traditionally, haemosporidian parasites of birds have been described based on the morphology of their blood stages and intensity of infection in the host. Their identification requires microscopic inspection of blood smears, from which different cell types of the parasite could be identified within host cells (Yohannes *et al.*, 2008). Blood-smear microscopy is a cost-effective way of identifying and quantifying parasites. However, microscopy reaches its limit of detection when parasitaemia falls below 40 infected red blood cells per microliter of blood which equates to one parasite per 10,000 erythrocytes (Bruce and Day, 2002). In contrast, PCR assays could be performed which encounter limits of detection if parasitaemia falls below 0.5 infected red blood cells per microliter of blood and are less constrained by technician's expertise (Zimmerman *et al.*, 2004). Comparing PCR with microscopy, out of 44 pigeons, 28 (63.63 per cent) were positive in PCR compared to 52.28

per cent in microscopy. Out of the four districts under study, *Haemoproteus* was found from Thrissur and Kozhikode with a prevalence rate of 60 per cent (15/25) and 100 per cent (8/8) respectively. Out of 28 birds with *Haemoproteus* infection, ectoparasite was found beneath the feathers in 14 (50 per cent) birds. Among these affected birds, *Pseudolynchia* was identified in nine pigeons from Thrissur (60 per cent) and five pigeons from Kozhikode (62.5 per cent).

Cloacal swabs from 44 pigeons were tested using antigen NDV kits (Bionote, Korea) and 28 were tested positive with a 63.63 per cent prevalence rate. The existence of avian paramyxovirus 1 in feral pigeons poses a potential threat to the poultry population since there is ample opportunity for mingling with poultry under open housing management. Pigeons can act as reservoir for pigeon paramyxovirus 1, which can cause zoonotic infection especially in immunocompromised patients (Kuiken *et al.*, 2018). Predominant clinical signs of avian paramyxovirus infection in racing pigeons were polydipsia, ataxia, poor balance, torticollis, head tremors, inability to fly, and diarrhoea that were unresponsive to therapy (Barton *et al.*, 1992). Out of the four districts, NDV was positive in all the four districts. Alappuzha (5/5) and Wayanad (6/6) showed 100 per cent prevalence while it was 64 per cent (16/25) in Thrissur and only 12.5 per cent (1/8) in Kozhikode. Paramyxoviral infections could be seen in pigeon lofts of all the four districts and this might be due to the presence of rock pigeons in and around the environment where these fancy pigeons are kept. Rock pigeons are considered as source of infection to other pigeons.

Out of the total 44 pigeons, only 10 pigeons showed *Salmonella* infection with a prevalence of 22.72 per cent. Similar finding observed by Osman *et al.* (2013) reported a prevalence of 13.3 per cent *Salmonella* infection in pigeons and highlighted their potential role as important carriers and spreaders of this zoonotic agent giving rise to public health problems. Out of the four districts, no isolates of *Salmonella* was found from Wayanad but Alappuzha, Thrissur and Kozhikode showed prevalence of 20 per cent (1/5), 20 per cent (5/25) and 50 per cent (4/8), respectively. Out of these ten isolates, eight (80 per cent) were sensitive for ceftriaxone, seven (70 per cent) sensitive for ceftriaxone tazobactam, six (60 per cent) for kanamycin and ofloxacin, five (50 per cent) for doxycycline, three (30 per cent) for enrofloxacin, two (20 per cent) for cefpodoxime and tobramycin and one (10 per cent) sensitive for amoxicillin clavulanate. All the isolates showed resistance to tetracycline, azithromycin, amoxicillin and ceftizoxime. The findings suggest that multidrug resistance strains are more likely to be of clinical significance because they pose a public health risk to the human population. The frequent reports on isolation of strains resistant to antibiotics from these birds generates the hypothesis of pigeons acting as reservoirs of resistance genes in their microbiota. This possibility would raise concern due to the zoonotic risk implied. Hence, control of these birds in the urban and animal production environments should be reinforced because of their potential reservoir role (Vasconcelos *et al.*, 2018).

Combined infections were present in the study with highest prevalence of 22.2 per cent (10/44) for paramyxovirus and *Haemoproteus* infection. *Haemoproteus* with *Salmonella* and paramyxovirus with *Salmonella* occurred in 6.81 per cent (3/44) samples each and combined infection of paramyxovirus, *Salmonella* and *Haemoproteus* was seen in 4.54 per cent (2/44) samples. Combined infections in the present study were mostly reported from Thrissur district and had combined paramyxovirus and *Haemoproteus* infection in 22 per cent (10/44), combined *Salmonella* and paramyxovirus infection in 4.5 per cent (2/44) and combined *Salmonella*,

paramyxovirus and *Haemoproteus* infection in 4.5 per cent (2/44). In Kozhikode district, *Haemoproteus* and *Salmonella* combined infection was observed in (6.8 per cent) (3/44) samples, while *Salmonella* and paramyxovirus infection concurrently occurred in 2.2 per cent (1/44) samples.

Summary

Neurological signs in pigeons were mainly associated with paramyxovirus followed by *Haemoproteus* and *Salmonella* infection. The present study provided evidence of combined infections in pigeons emphasising the paramount importance of diagnosing multiple infections and treating for each of these infections to ensure sustainable control. The study also throws light in to the existence of drug resistant strains.

Acknowledgment

The authors gratefully acknowledge the technical support of Kerala Veterinary and Animal Sciences University, Pookode, Kerala, India for conducting the research.

Conflict of Interest

Authors declare no conflict of interest

References

- Ali, A., Siddique, N., Abbas, M.A., Rafi, M.A. and Naeem, K. 2014. Rehabilitation and curing of Domestic Pigeons Exhibiting Signs of Torticollis. *Res. J. Vet. Pract.* **2**: 105-107.
- Barrow, G.I. and Feltham, R.K.A. 1993. *Cowan and Steel's Manual for the Identification of Medical Bacteria*. 3rd Edition, Cambridge University Press, Cambridge, 331.
- Barton, J.T., Bickford, A.A., Cooper, G.L., Charlton, B.R. and Cardona, C.J. 1992. Avian paramyxovirus type 1 infections in racing pigeons in California. I. Clinical signs, pathology, and serology. *Avian dis.* **36**: 463-468.

- Bauer, K.A., Sherris, J. and Turk, M. 1966. Antibiotic susceptibility testing by standardized single disc method. *Am. J. Clin. Pathol.* **45**: 493-496.
- Bruce, M.C. and Day, K.P. 2002. Cross-species regulation of malaria parasitaemia in the human host. *Curr. Opin. Microbiol.* **5**:431-437.
- Hooimeijer, J. and Dorrestein, G.M. 1997. Pigeons and doves. In: Altmann RB, SL Clubb, Dorrestein GM, Quesenberry KE.(eds.) *Avian Med. and Surg.* W. B. Saunders Co., Philadelphia, Pennsylvania. 244–257p.
- Joshi, V., Dimri, U., Alam, S. and Gopalakrishnan, A. 2017. Buparvaquone therapy in a rock pigeon infected with *Haemoproteus columbae* showing torticollis. *J. Parasit. Dis.* **41**: 514-516.
- Kheirabadi, K.P., Samani, A.D., Baberi, N.A. and Najazadeh, V. 2016. A first report of infestation by *Pseudolynchia canariensis* in a herd of pigeons in Shahrekord (Southwest of Iran). *J. Arthropod-Borne Dis.* **10**: 426-430.
- Kuiken, T., Breitbart, M., Beer, M., Grund, C., Hoper, D., van den Hoogen, B., Kerkhoffs, J.H., Kroes, A.C., Rosario, K., van Run, P. and Schwarz, M. 2018. Zoonotic infection with pigeon *paramyxovirus type 1* linked to fatal pneumonia. *J. Infect. Dis.* **218**: 1037-1044.
- LaPointe, D.A., Goff, M.L. and Atkinson, C.T. 2005. Comparative susceptibility of introduced forest dwelling mosquitoes in Hawai'i to avian malaria, *Plasmodium relictum*. *J. Parasitol.* **91**:843–849. ■
- Osman, K.M., Mehrez, M., Erfan, A.M. and Nayerah, A. 2013. *Salmonella enterica* isolated from pigeon (*Columba livia*) in Egypt. *Foodborne Pathog. Dis.* **10**: 481-483.
- Paul. T.K., Amin, M.R., Alam, M.A., Rahman, M.K., Sarker, Y.A. and Rizon, M.K. 2015. Occurrence of pigeon diseases at Khulna Sadar, Bangladesh. *Bangl. J. Vet. Med.* **13**:21-25.
- Quinn, P.J., Carter, M.E., Markey, B. and Carter, G.R. 2004. *Veterinary Clinical Microbiology*. Wolfe Publication, London, UK. 13p.
- Shinde, N.G., Gatne, M. and Singh, A. 2008. Prevalence of parasites in pigeons (*Columba livia domestica*) of Mumbai. *J. Vet. Parasitol.* **22**:65-66.
- Vasconcelos, R.H., Teixeira, R.S.D.C., Silva, I.N.G.D., Lopes, E.D.S. and Maciel, W.C. 2018. Feral pigeons (*Columba livia*) as potential reservoirs of *Salmonella sp.* and *Escherichia coli*. *Arq. Inst. Biol.* **85**:1-6.
- Yohannes, E., Hansson, B., Lee, R.W., Waldenström, J., Westerdahl, H., Akesson, M., Hasselquist, D. and Bensch, S. 2008. Isotope signatures in winter moulted feathers predict malaria prevalence in a breeding avian host. *Oecologia.* **158**: 299-306.
- Zimmerman, P.A., Mehlotra, R.K., Kasehagen, L.J. and Kazura, J.W. 2004. Why do we need to know more about mixed *Plasmodium* species infections in humans? *Trends Parasitol.* **20**:440-447.