



SURGICAL MANAGEMENT OF GYNECOMASTIA IN A SIROHI BUCK BY MASTECTOMY

Received - 25.01.13

Accepted - 10.03.13

Gynecomastia in bucks is a glandular tissue proliferation leading to unilateral or bilateral enlargement of mammary glands with occasional secretory activity (Oskam *et al.*, 2005). The condition has been reported among Nubian (Wooldridge *et al.*, 1999) and Polish White (Jaszczak *et al.*, 2010) goats. The age of occurrence varies from seven months to several years and milk yield from 20 ml to 1500 ml/day (Marx *et al.*, 1975). The cytological, histological, hormonal and semen quality of the bucks are usually unaffected (Jaszczak *et al.*, 2010). In this article the occurrence of bilateral gynecomastia in a two year old Sirohi buck and its surgical correction is reported.

A Sirohi buck, aged two years, was

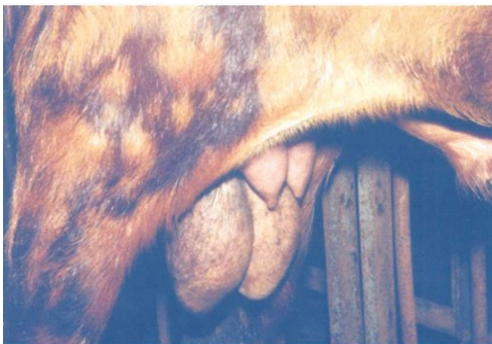

Fig.1. Early appearance of enlarged glandular tissue.

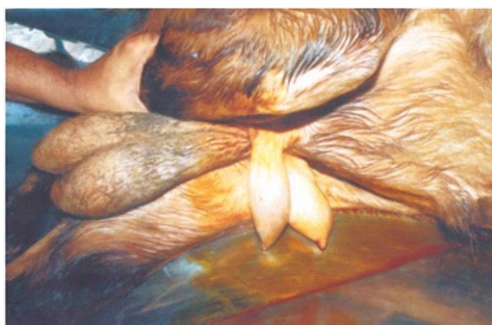


Fig. 2 Pendulous glands after one month

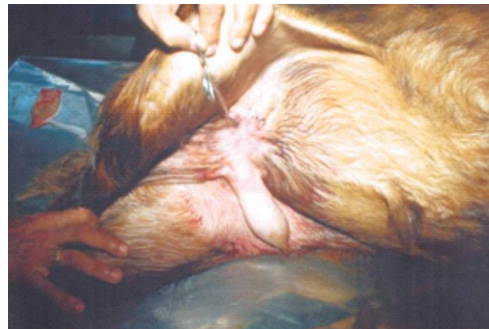

Fig. 3. Individual surgical removal and closure presented to the Veterinary Polyclinic, Kunnankulam with a history of abnormal growth near the testes. The buck was purchased four months before and was being utilised as a stud. It had showed normal male phenotype from birth to puberty and had sired 11 kids before purchase by the present owner. Enlargement of mammary glands became apparent two months after purchase (Fig 1). At the time of examination both glands were well developed (Fig.2) with secretion of approximate yield of 25 ml of milk from each Appetite, activities and libido of the animal were unaffected. Mastectomy of the animal was undertaken at the request of the owner of the animal.

Xylazine @ 0.1mg/kg body weight given intramuscularly, followed by local infiltration of 7ml of xylocaine 2% solution provided sedation and analgesia. Elliptical incisions were placed below the base of each half with retention of enough skin for complete apposition after removal. Blunt dissection was used to separate the gland from the skin. External pudental artery and external pudental vein were ligated. Both glands were removed separately (Fig 4). Scrotal/mammary lymph nodes were not resected. Subcutaneous sutures with plain silk (No.2) were placed in order to obliterate dead space. Continuous sutures with braided silk (No.2) were used for

closure (Fig 5). Post operative care included Tetanus Toxoid one ml and Meloxicam @ 0.3 mg/kg body weight followed by Streptopenicillin injection @ 10,000 IU /kg body weight for five days. Recovery was uneventful.

Gynaecomastia is more frequent among bucks compared to rams and bulls. Familial predisposition, endocrine imbalances and manipulation of rudimentary teats either by the animal or other animals have been implicated as possible predisposing causes. But the condition has not yet been conclusively interpreted based on cytological, hormonal or seminal aberrations. In the present case, the animal also had normal values for the clinical parameters. Mastectomy was performed since the condition is presumed to predispose the animal to mammary tumours or eventual reduction in fertility.

Summary

A case of gynaecomastia and its surgical correction in a Sirohi buck is reported and discussed.

References

- Jaszczak, K., Sysa, P., Romanowicz, K., Boryczko, Z., Parada, R., Sacharczuk, M., Witkowski, M., Kawka, M. and Horbanczuk, K. 2010. Cytogenetic, histological, hormonal and semen studies in male goats with developed udders. *Animal Science Papers and Reports*. **28**: 71-80
- Marx, D., Klemp, J., Loeffler, K. and Bohm, S. 1975. Gynecomastia in a male goat. I. Sexual activity and sperm and milk quality. *Zuchthygiene*. **10**: 125-34
- Smith, MC and Sherman, D. M. 1994. *Goat Medicine*. Lea and Febiger., Philadelphia. 446-63
- Wooldridge, A A., Gill, M S., Lemarchand, T., Eits, B., Taylor, H W and Otterson, T (1999). Gynecomastia and mammary gland carcinoma in a Nubian buck. *Can Vet. J.* **40**: 663-65
- Oskam, I .C., Lyche, J L., Krogenaes, A., Thomassen, R., Skaare, J.U., Wiger, R., Dahl, E., Sweeney, T., Stien, A and Ropstad, E. 2005. Effect of long term maternal exposure to low doses of PCB 126 and PCB 153 on the reproductive system and related hormones of young male goats. *Reproduction*. **130**: 731-32.

K. Vinod Kumar¹

Department of Veterinary Epidemiology and Preventive Medicine, College of Veterinary and Animal Sciences, Mannuthy-680651, Thrissur, Kerala



¹.Assistant Professor