



ULTRASONOGRAPHIC DIAGNOSIS OF CIRRHOSIS IN A DOG

Anju Anna James¹ and Usha Narayana Pillai²

Department of Clinical Veterinary Medicine
College of Veterinary and Animal Sciences
Mannuthy -680 651, Thrissur, Kerala

Received - 04.03.11

Accepted - 18.10.11

Abstract

A male boxer dog aged about 11 months with a body weight of 20 kg was referred to the Veterinary Hospital, Mannuthy with the history of anorexia, lethargy, melena and abdominal distension since three weeks. Based on the clinical examination, ultrasonographic findings, serum biochemistry, physical characteristics of the ascitic fluid and liver biopsy, the case was diagnosed as ascitis due to hepatic cirrhosis. The animal was success fully treated with Frusemide, Silymarin and Essential amino acids.

Keywords: Dog, Ascitis, Cirrhosis, Ultrasonography.

Cirrhosis refers to the end stage liver disease with necrosis, fibrosis, hepatocyte degeneration and marked architectural distortion (Anderson and Sevelius, 1991). The present paper describes the ultrasonographic diagnosis of hepatic cirrhosis in an intact male boxer dog and its successful therapeutic management.

Materials and Methods

A male boxer dog aged about 11 months with a body weight of 20 kg was referred to the Medicine unit of Veterinary College Hospital, Mannuthy with the history of anorexia, lethargy, melena and abdominal

distension since three weeks. Vaccination and deworming schedules were noted as regular. Detailed clinical examination of the dog was carried out. On abdominal palpation, fluid thrill could be felt. Animal was subjected to ultrasonographic examination which revealed ascitis and liver abnormality. Urine sample was collected for routine analysis and serum samples for estimating total protein, albumin, globulin, A:G ratio, BUN, direct and indirect bilirubin and Alkaline phosphatase (ALP) enzyme. Ascitic fluid was also collected for estimating protein level. Ultrasonography aided liver biopsy was also performed.

Results and Discussion

Routine clinical examination revealed temperature (101.8°F), pulse (150/min), respiratory rate (48/min) and a pale roseate mucous membrane. On abdominal palpation, fluid thrill could be felt. The wet film and faecal sample examination were negative for the presence of any parasite. Result of urine analysis was unremarkable.

The ultrasonography of liver revealed irregular hepatic margins and increased parenchymal echogenicity associated with fibrous tissue and ascitis (Fig.1). Kidneys were found to be of normal size and cortico-medullary distinction was clear. The ultrasonographic finding was suggestive of hepatic cirrhosis.

¹ Post Graduate Scholar

² Associate Professor

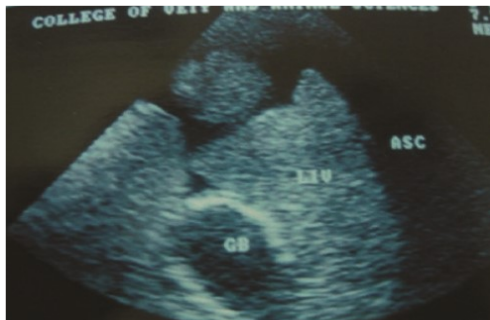

Fig.1 Anechoic area suggestive of fluid and irregular hepatic margins.

Serum biochemistry revealed hypoproteinemia (4.4g/dl) with hypoalbuminemia (1.3g/dl) and normal globulin level (3.1g/dl) reduced A:G ratio (0.4), hypourcemia (BUN-8mg/dl), normal bilirubin levels (total-0.2mg/dl, direct-0.1mg/dl, indirect-0.1 mg/dl) and elevated serum ALP level (609U/L). Ascitic fluid collected was found to be a clear transudate with protein level 0.2g/dl.

Ultrasonography aided liver biopsy was performed and histopathology revealed pseudolobulation and atrophy of hepatocytes (Fig.2). Based on these findings, the case was diagnosed as ascites due to cirrhosis.

Animal was treated with Tab. Lasix (Frusemide) @ 2mg/kg bodywt twice daily, Tab. Silybon (Silymarin) @ 10mg/kg bodywt twice daily and Tab. Essentiale-L (Lecithin) 250mg once daily for 15 days and advised review after 15 days. Considerable improvement was noticed after 15 days. Abdominal distension was markedly reduced. The owner was advised to continue Tab. Silybon and Tab. Essentiale-L for two more months.

Clinical signs of hepatic cirrhosis include anorexia, lethargy, depression, vomiting, diarrhea, polyuria and polydipsia (Johnson, 2000). Melena and, or haematemesis consequent to gastric ulceration were observed in cirrhosis and ascites was a common clinical finding (Sevelius, 1995). Diseases involving the liver are the most common causes of ascites. Increased portal pressure, decreased albumin production and increased sodium retention ultimately resulted in the development of ascites. Intrahepatic portal hypertension associated with cirrhosis leads to the

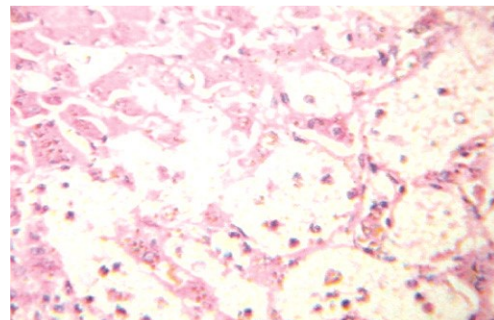


Fig.2 Pseudolobulation and atrophy of hepatocytes
H&E x400

production of a large volume of relatively low protein containing hepatic lymph (Johnson, 2000). Mean serum albumin concentration in dogs with cirrhosis was significantly reduced when compared to other liver diseases. The sensitivity of albumin to detect cirrhosis was 96 percent while for chronic non specific hepatitis, it was 16.7 percent and hypoalbuminemia was an important marker of chronic inflammatory liver disease (Sevelius, 1995). In about 100 percent of dogs with chronic active hepatitis, serum ALP level was elevated almost five times the normal (Strombeck and Gribble, 1978). Increased serum ALP level in cirrhosis might be due to cholestasis secondary to intrahepatic biliary obstruction. BUN level is found to be reduced in all types of chronic hepatitis. In this case, the serum biochemistry was in agreement with the ultrasonographic finding and thus the case was diagnosed as hepatic cirrhosis.

References

- Anderson, M. and Sevelius, E. 1991. Breed, sex and age distribution in dogs with chronic liver disease: a demographic study. *J. Small Anim. Pract.*, **31**:1-5.
- Johnson, S. E. 2000. Chronic hepatic disorders. In: Ettinger, S.J. and Feldman, E.C (Eds.). *Textbook of veterinary internal medicine*. 5th ed. W. B. Saunders Co., Philadelphia. pp: 1298-1325.
- Sevelius, E. 1995. Diagnosis and prognosis of chronic hepatitis and cirrhosis in dogs. *J. Small Anim. Pract.*, **36**:521-528.
- Strombeck, D. R. and Gribble, D. 1978. Chronic active hepatitis in the dog. *J. Am. Vet. Med. Assoc.*, **173**:380-386. □